

Evaluation of positioning accuracy in head-and-neck cancer treatment: A cone beam computed tomography assessment of three immobilization devices with volumetric modulated arc therapy

Noor Mail^{1,2*}, Khalid M. Alshamrani^{1,3,4}, Rab Nawaz Lodhi^{1,4}, Eman Khawandanh^{1,4}, Amani Saleem^{1,4}, Batoor Khan⁵, Majed Alghamdi^{1,4}, Mohammed Nadershah⁶, Majid S. Althaqafy^{1,3,4}, Ahmed Subahi^{1,4,7}, Suliman M. Alghamdi^{1,4}

¹Ministry of the National Guard - Health Affairs, Jeddah, Saudi Arabia

²Radiation Oncology Hillman Cancer Center, University of Pittsburgh Medical Center, Pittsburgh, PA, United States of America

³College of Applied Medical Sciences, King Saud bin Abdulaziz University for Health Sciences, Jeddah, Saudi Arabia

⁴King Abdullah International Medical Research Center, Jeddah, Saudi Arabia

⁵Department of Life Sciences, University of Toronto Mississauga, Mississauga, Canada

⁶Department of Oral and Maxillofacial Surgery, Faculty of Dentistry, King Abdulaziz University, Jeddah, Saudi Arabia

⁷College of Sciences and Health Professions, King Saud bin Abdulaziz University for Health Sciences, Jeddah, Saudi Arabia

Abstract

In this study, we assessed the precision and repeatability of the daily patient positioning for three distinct immobilization devices used for head-and-neck patients undergoing RapidArc radiation therapy using cone beam computed tomography (CBCT). An analysis was conducted on the accuracy of patient setup for three distinct immobilization devices, resulting in 1204 CBCT images for 189 patients in total. Using a typical posifix supine headrest and five fixation point podcast-plus-thermoplastic masks, the first group of 39 patients (125 CBCTs) was immobilized. The identical method was used to immobilize the second group of 19 patients (158 CBCTs) in the same posture (supine), and AccuFormTM custom headrests were employed as an added measure. Over 65% of the patients in the third group had a double shell positioning system (DSPA) covering their entire head and neck. Patient-alignment-accuracy or couch shifts in the vertical, longitudinal, and lateral directions from CT-CBCT fusions were recorded from ARIA. Our results showed that in 90% of the anterior-posterior (AP), 90% of the superior-inferior (SI), and 92.7% of the right-left (RL) population in the first group, patient-alignment-accuracy or couch shifts were within 2 mm. For 99.4% (AP), 100% (SI), and 98.7% (RL) of the second group's total population, patient-alignment-accuracy was within 2 mm. In the third group, it was within 2 mm for 92.1% (AP), ~89% (SI), and 93.3% (RL) of the total population. In conclusion, a significant improvement was seen with the application of a mouth bite and a tailored backrest cushion to the five fixation point posicast mask. In addition, significant improvement in the alignment of the lower neck area was observed with the use of DSPA. Virtually 100% of the head-and-neck patients were aligned within an accuracy of 3 mm, which is the PTV margin in our department.

Keywords: Radiotherapy, RapidArc, Immobilization, Head-and-neck tumor, Patient-setup, Mask system, Radiation Oncology

1. INTRODUCTION

An accurate and repeatable patient setup is very important in radiotherapy to precisely target the tumor and minimize the irradiation of healthy tissues for fractionated radiotherapy [1]. An immobilization device helps the patient stay in the same position for all radiation treatments and each fraction [2]. Various studies have discussed the importance of patient setup in head/neck and skull/brain tumors [3-17]. According to these studies, precise delivery on a daily basis is crucial for treatment success. The thermoplastic mask is the most commonly used immobilization device for fractionated radiotherapy to the head-and-neck region [18]. There are different types and manufacturers of thermoplastic

***Corresponding author:**
Noor Mail (mailto:upmc.edu)

This is an open-access article under the terms of the Creative Commons Attribution License, which permits use, distribution, and reproduction in any medium, provided the original work is properly cited.

© 2024 Author(s)

Received: 29 July 2024; Revision received: 21 August 2024;
Accepted: 27 August 2024; Published: 12 September 2024

How to cite this article: Mail N, Alshamrani KM, Lodhi RN, *et al.* Evaluation of positioning accuracy in head-and-neck cancer treatment: A cone beam computed tomography assessment of three immobilization devices with volumetric modulated arc therapy. J Biol Methods. 2024;11(3):e99010025. DOI: 10.14440/jbm.2024.0047

masks, several of which have been investigated in both prospective [19] and retrospective [20] studies.

All immobilization systems designed for radiation treatment should meet several conditions [21]. The ability to reduce positioning errors and limit patient movements is considered crucial. Good patient comfort and a short construction time by radiotherapy technologists are also important factors [22]. The conventional head-and-neck immobilization device used in our department was the five fixation point posicast-plus thermoplastic mask with a standard posifix supine anterior/posterior headrest and double shell. The posture fixation of patients during treatment becomes a significant procedure and exerts a direct impact on positioning accuracy [23]. Although the thermoplastic system works well in clinical practice, the image-guided radiation therapy (IGRT) technology introduced in the last decades has allowed for the verification of patient positioning and geometry. A Cone Beam Computed Tomography (CBCT) taken before the treatment provided 3D images [24–27]. A customized headrest was assessed by Humphreys *et al.* for the head-and-neck IMRT treatment [28]. They reported that a customized headrest could achieve alignment accuracy within 3 mm.

The primary objective of the current study was to retrospectively assess and compare the random uncertainties in patient positioning differences between online and offline use of three immobilization systems for the head-and-neck region. A mouth bite with a thermoplastic mask was added to limit head rotation. To stabilize the neck curvature and limit dispositions of the head in the right-left (RL) and superior-inferior (SI) directions, a customized cushion was also integrated to the standard headrest and molded to the posterior aspect of the head and neck. In addition, we reported the limitations of customized headrests for stabilizing neck curvature in patients with short and long necks. Moreover, we reported another type of immobilization system, i.e., the double shell positioning system (DSPS). Keywords of the concept were simplicity, reproducibility, and patient-friendliness. The DSPS replaced the headrest and cushions under the head-and-neck area. The posterior shell can adopt the patient's natural supine posture and thus it was easy to reproduce even toward the end of treatment. While the anterior is rigid and molded around the head-and-neck area to limit the patient's movement before and during the treatment. The data of each group were gathered and analyzed to evaluate the effect of each added accessory separately. Furthermore, we used customized headrests for all head-and-neck cases, and for patients with short and long necks, it was quite difficult to stabilize neck curvature. In evaluating the effectiveness of various immobilization systems for head-and-neck cases, it is essential to examine whether specific modifications can

significantly improve patient stability during treatment. To this end, we formulated a null hypothesis: The addition of a mouth bite and a customized headrest does not significantly limit the rotation of the head region, stabilize the neck curvature, or minimize the longitudinal and lateral displacement of the head-and-neck in head-and-neck immobilization systems. This hypothesis served as the basis for our investigation, guiding the analysis of whether these modifications could provide measurable improvements in patient alignment.

2. METHODS

2.1. Patient data and immobilization devices

Between July 2021 and July 2023, a retrospective study was conducted on a population of 370 patients, all diagnosed with various cancers in the head-and-neck region, including the nasal cavity, paranasal sinus, nasopharyngeal cancer, oral and oropharyngeal cancer, salivary glands, larynx, parotid, maxilla, and thyroid tumors. Using the Raosoft® sample size calculator with a 5% margin of error and a 95% confidence level [29], a recommended sample size of 189 was determined for this study. Patients with tumors below the clavicles and certain skull base tumors were excluded due to the challenges in immobilizing these areas, given the rigid relationship of the target to the skull.

This study was performed on 189 patients, involving 1204 CBCT images. The data were analyzed offline, and the applied CBCT shifts for online and offline alignment accuracy were compared among three groups to quantitatively evaluate the position of random uncertainties with the new system. The offline CBCT and CT fusion were done by a physicist and carefully reviewed by the radiation oncologist specializing in head-and-neck cancer. About 25–30% and 20–25% of patients with Nasopharynx cases were included in the first and second groups, respectively. While about 40–50% of Nasopharynx cases were included in the third group. Patients were not grouped based on any factor (gender, age, treatment intent, duration, or technique of treatment) other than the type of immobilization device used because the only aim of this study was to compare the three immobilization systems, including (1) the conventional immobilization system (CIS), (2) New immobilization system (NIS), and (3) DSPS.

2.2. Ethical considerations

The ethics committee at the King Abdullah International Medical Research Center (KAIMRC) approved this study (Study Number: SP21J/095/03). The data were accessed for research purposes on September 31, 2021. The following methods of data anonymization were employed:

A- Removal of identifiers: The data were fully anonymized. Any information that could directly or indirectly identify

individual participants was removed or altered before the data were accessed by the researchers. This process ensured that the data could not be traced back to any specific individual.

- B- Access control: The data were stored in a password-protected Microsoft Excel file. This step added an additional layer of security, ensuring that only authorized personnel could access the data.

Steps to ensure data integrity and confidentiality included:

- A- Ethics approval: The study was approved by the ethics committee at the KAIMRC, ensuring that the research met ethical standards, including those related to data protection.
- B- Informed consent: Written informed consent was obtained from all participants before data acquisition. This step ensured that participants were aware of how their data would be used and that they agreed to these terms.
- C- Controlled access: Researchers did not have access to any information that could identify individual participants during and after data collection. This controlled access to sensitive data helped maintain confidentiality.
- D- Data anonymization before access: All data were anonymized before the researchers had access to them, ensuring that the data could not be linked to any individual participants.
- E- Confidentiality measures: Anonymity and confidentiality were rigorously upheld throughout the study. The use of a password-protected file without identifiers demonstrates a commitment to maintaining the confidentiality of participant data.

2.3. Immobilization systems

For many years, we have been using a standard five fixation point posicast-plus thermoplastic mask with a posifix supine headrest. However, we faced difficulties in realigning patients on a daily basis, i.e., rotation on the zygomatic arch during brain treatment and anterior/posterior placement on the lower neck from C3 to C7. Then, we added a customized headrest (cushion). Nonetheless, the rotation improved, and the head-and-neck alignments were yet to be fixed for patients with short and very long necks. Finally, we changed the immobilization devices and used DSPS shells to obtain a better setup for most of the patients. We successfully reproduced the same setup on a daily basis and eventually adopted the DPSP system. As it locks and supports the lower supine position, there was a minimal shift in all directions.

2.3.1. CIS

The first group of 39 patients was immobilized in the supine position with five posicast-plus thermoplastic mask

fixation points (head and shoulders). The five-point mask was fitted to the carbon fiber baseplate (indexed onto the couch top) laterally on both sides of the shoulders as well as the head. A fifth cranial flap was fixed to the baseplate in the superior aspect of the head. To soften, the thermoplastic mask was submerged in a hot water bath (70°–71°) for 1 min. The mask was placed directly on the patient's head and shoulders. The patient's head was supported by supine posifix standard headrests made of low-density polyethylene foam in five color-coded different shapes to choose the best fit for the patient's neck and to obtain different neck positions (Figure 1A).

2.3.2. NIS

The second group of 19 patients was immobilized in the same position (supine) using the same system complemented with AccuForm custom headrests. These cushions were soft, cloth-covered pillows filled with beads coated in water-curable resin. The cushion used was of a large size (20 × 25 cm). It was briefly rinsed under tap water to become pliable. It was then cantered under the patient's head and molded to the patient's posterior contour. After a few minutes, the cushion formed a rigid yet comfortable customized headrest. In addition, this group also had a precise mouth bite manufactured before the thermoplastic mask. The mouth bite was submerged in hot water to soften and then placed in the patient's mouth. Initially, the patient was advised to bite hard to leave a proper dental impression on the mouth bite. After the mouth bite set, the thermoplastic mask was pulled over the patient and the docking plate was snapped on top of the mouth bite to secure it to the mask (Figure 1B).

2.3.3. DSPS

The third-largest group consisted of 131 patients who were immobilized with DSPS. This group had the same concept as the aforementioned two studies but with the exception of the posterior (Base Shell) difference. The DSPS concept was created around an ultra-light carbon fiber cradle/base plate with maximum accessibility for the preparation of individual masks. The DSPS system is equipped with two different moldable thermoplastic sheets which are fixed in precisely fitted frames. While the material is flexible, it shows sufficient resistance to support the head of the patient during the molding process. At the same time, it is adequately pliable to customize the mask for each patient. The molding and application processes were the same but the post-shell was first dipped in warm water (70°–71°C) for 20 s. The post-shell took 5 min to set and then the anterior shell was kept in warm water for 2–3 min and then applied to the patient's face, neck, and shoulder (Figure 2).




Figure 1. (A) The conventional immobilization system for head and neck, (B) Customized immobilization system for head and neck.

Source: <https://ngha.med.sa/English/MedicalCities/Jeddah/MedDepartments/PNOC> [44].




Figure 2. New double shell positioning system (double-shell-positioning-system™) for the immobilization of head and neck.

Source: <https://ngha.med.sa/English/MedicalCities/Jeddah/MedDepartments/PNOC> [44].

2.4. Planning CT

A helical CT scan was performed in all patients with an intravenous contrast using 120 kV, 120 MAs, a slice thickness of 2 mm, an extended field of view of 65 cm, and a pixel size of 1.27 mm × 1.27 mm. The scan started from the top of the head and finished 5 cm below the clavicles. The zero slices were marked on the mask as a CT origin reference using a superfine (0.3 mm) permanent marker on silk tape. The zero slices were positioned in a relatively stable location to facilitate reproducibility in the treatment room. CT Simulator room laser system (LAP Iso-Mark, Germany) features one ceiling-mounted movable sagittal laser (RL) and two floor-mounted movable horizontal lasers (anterior-posterior [AP]) with a fixed transverse laser (SI).

2.5. Treatment units

The patients were treated on one of the two linear accelerators Trilogy TX and Trilogy HD (Varian Medical Systems, Palo Alto, CA). Both machines are equipped with an On-Board Imaging Device (OBI). For the treatment, the patient was repositioned in the same immobilization device manufactured in the CT stimulation session. The first step was to position the customized headrest/DSPS perfectly in relation to the standard headrest. As the patient lied down, the therapist observed how the head of the patient fitted into the headrest or posterior shell. If any gap was noticed, the patient was advised to move accordingly to obtain the exact fit. The therapist would assess the straightness of the patient's body anatomically (SSN and Xiphoid) using the sagittal laser. It was crucial to fit the mask to the patient's facial anatomy first and then align it to the corresponding slots in the base plate before fixing it. It was also important to clip the mask to the base plate from both sides at the same time to avoid rotating the head. The in-room wall-mounted lasers were aligned with the visual external markers drawn on the mask during the CT simulation as a reference. The midline tattoo was utilized to further aid the straightening of the body in the RL direction.

2.5.1. IGRT: OBI and CBCT systems

The OBI device consists of an X-ray source and detector mounted on a single exact arm perpendicular to the gantry of the linear accelerator. The 2D/2D kV images are usually taken in the anterior and right lateral direction and can be reviewed against radiographs digitally reconstructed from the planning CT. The CBCT was performed by rotating the X-ray source around the patient from 22° to 178° and a projection was captured every ten degrees of a scanning field width (longitudinally) of 18 cm. The CBCT for the head-and-neck region was acquired with a full-fan bowtie filter. The head-and-neck CBCT exposure parameters are typically 80 kV, 25 mAs, and 8 mS using a 2.5 mm slice thickness and pixel size of 0.65 mm × 0.65 mm. The acquired images were reconstructed and registered to the reference planning CT on the OBI software (version 1.6). The radiation therapist reviewed the fused images on the coronal, sagittal, and axial planes to examine anatomical matches and made any necessary adjustments under the instruction of the radiation oncologist (Figure 3). The set-up error was identified in terms of anatomical displacement between the acquired CBCT and the reference planning CT and expressed as translational couch shifts in three directions, i.e., RL, SI, and AP directions. If a rotational error was significant (more than 3°), the patient was re-positioned and re-imaged. A second radiation therapist verified the anatomical match identified to minimize operator error. Once satisfactory, the patient's position was corrected by automatic and remote couch re-positioning. The isocenter was

re-marked on the mask after the couch adjustment on day 1 and the new mark was used to position the patient for subsequent days. Following the departmental imaging protocol, all patients underwent CBCT on day 1, followed by daily 2D/2D kV imaging and weekly CBCT. The applied CBCT shifts were collected from the Offline Review Application (ARIA verification system 13.7) for analysis. A total of 1204 CBCT were analyzed, and 125 of them belonged to the first group, 158 to the second group, and 921 CBCT were taken in the third group. Only CBCT images were analyzed. All positioning and imaging components such as OBI, laser, field size, and table movements were checked daily for image quality and geometric accuracy with a tolerance of ± 2 mm for both the CT simulator as well as the linear accelerator.

2.6. Data analysis

Accuracy of patient alignment in each group was evaluated in terms of the translational shift difference between online and offline CBCT and reference CT fusions. The applied 3D (RL, SI, and AP) shifts for the online and offline alignment were collected from ARIA applications for each CBCT and each patient. For each axis, the mean value (M) and standard deviation (SD) of all errors were also calculated. Percentages of CBCTs with shifts >2 mm (both + and -) were calculated for the three groups. A 2-mm shift was chosen as a threshold because a margin of 2–3 mm is often employed by oncologists when planning Rapid Arc head-and-neck cases. The Kruskal–Wallis test was utilized to evaluate the mean shift differences among the three immobilization systems across the longitudinal, vertical, and lateral axes. The level of significance (α) was set at <0.05 .

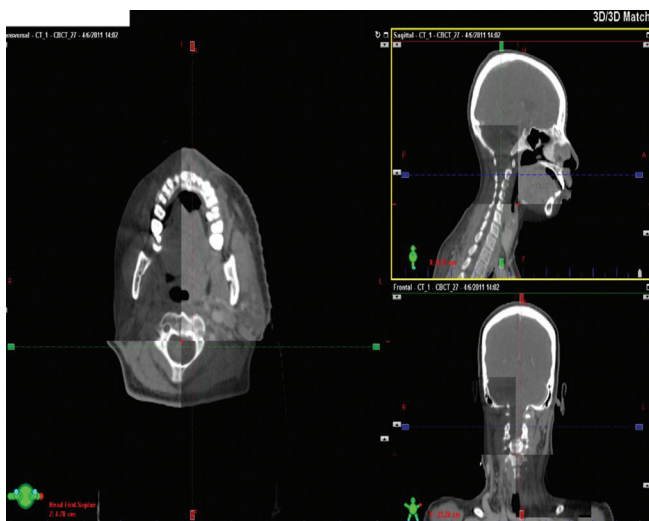

Figure 3. Modified image-guided radiation therapy, and anatomy match performed on cone beam computed tomography (CT) image fused to planning CT.

Source: <https://ngha.med.sa/English/MedicalCities/Jeddah/MedDepartments/PNOC> [44].

3. RESULTS

A total of 1204 CBCT images were analyzed, and 125 of them were obtained from the first group of patients immobilized using the conventional system and 158 from the second group immobilized using the new system. With DSPS, 921 CBCT images were taken and analyzed.

Figures 4-6 show the patient's alignment percentage as a function of the translational shift difference between online and offline alignment in the longitudinal, lateral, and vertical directions for three different immobilization systems, respectively. For the conventional immobilization group, translational shift differences greater than 2 mm were observed in 22.4%, 13.6%, and 28.0% of SI, left-right, and AP directions. For the new immobilization group, translational shift differences >2 mm were observed in 2.5%, 2.0%, and 0.6% of SI, left-right, and AP directions, respectively. While translational shift differences of more than 2 mm were seen in 11.5%, 6.7%, and 7.9% in SI, left-right, and AP directions, respectively, for DSPS shells dubbed the third group, translational shift differences above 2 mm were seen between offline and online alignments. The NIS yielded better results in terms of a minimum shift in all three directions, which might be attributed to NIS-treated nasopharyngeal cases being less than those in the third group. For the conventional system, the translational shift applied to the higher population in the SI direction was due to the curved nature of the headrest in the SI direction only, leaving a gap between the patient's head and the mask on both sides of the head. These remaining gaps left room for displacement and rotation of the head in the longitudinal direction. The DSPS showed more vertical (AP) improvements in the lower C-spine, which maintained the natural spinal curve from the beginning until the end of the treatment, compared with the conventional group. Table 1 summarizes the mean shift differences (in mm),

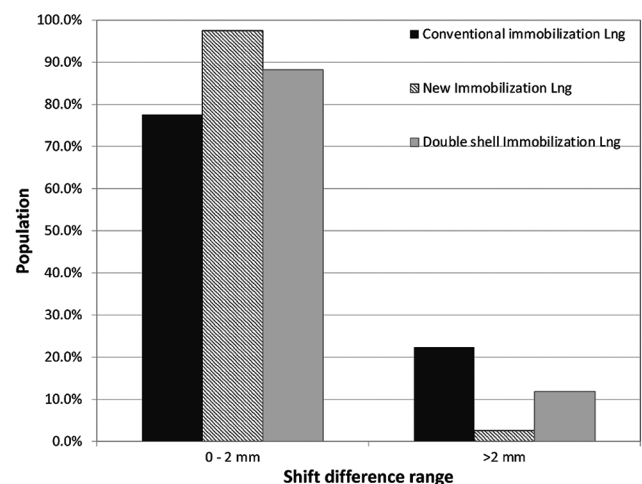


Figure 4. Percentage of patient's alignment as a function of the longitudinal translational shift difference (online-offline).

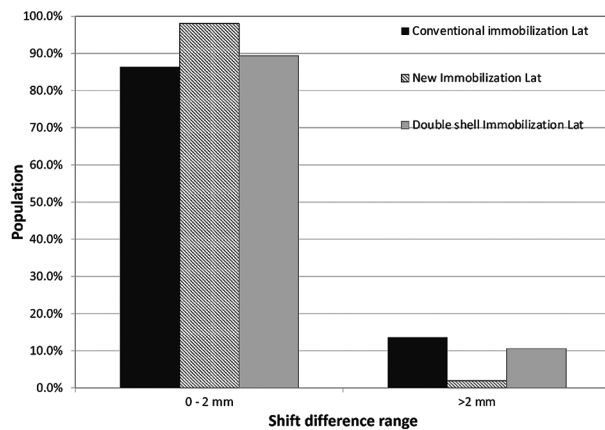


Figure 5. Percentage of patient's alignment as a function of the lateral translational shift difference (online-offline).

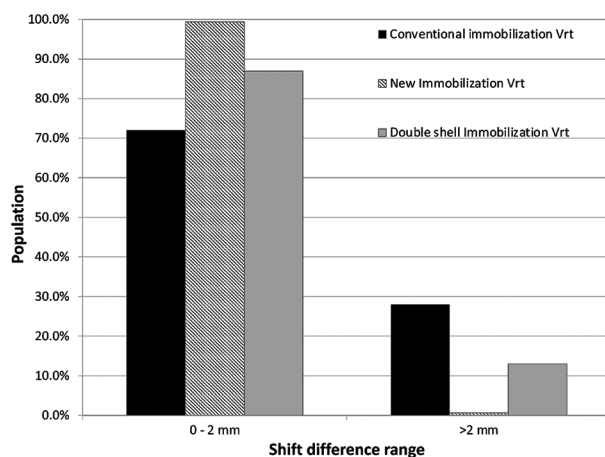


Figure 6. Percentage of patient's alignment as a function of the vertical translational shift difference (online-offline).

Table 1. Mean shift differences for three different immobilization devices

Shift axis	Immobilization system	Mean shift difference (mm)	Standard deviation	P-value
Longitudinal	CIS	1.212	±0.41	0.088
	NIS	0.832	±0.43	
	DSPS	0.984	±0.38	
Vertical	CIS	1.003	±0.39	0.688
	NIS	1.047	±0.41	
	DSPS	1.119	±0.31	
Lateral	CIS	1.074	±0.33	0.287
	NIS	0.848	±0.37	
	DSPS	0.961	±0.40	

CIS: Conventional immobilization system; DSPS: Double shell positioning system; NIS: New immobilization system

standard deviations, and corresponding P-values for three immobilization systems (CIS, NIS, DSPS) across the longitudinal, vertical, and lateral axes. The NIS system consistently demonstrated lower mean shift differences, particularly in the longitudinal and lateral axes, although these

differences were not statistically significant. The CIS system shows the highest mean shift differences, suggesting it might be less effective in minimizing movement. The DSPS system exhibited moderate performance across all axes but did not show a significant improvement over CIS.

Figure 4 shows that the longitudinal shift (SI) significantly improved with the new immobilization device as well as DSP. Furthermore, it exhibits that approximately 78% of the population were aligned within the CIS range (2 mm). New immobilization with a customized headrest and mouth bite resulted in an alignment within 2 mm in 97.5% of the population. The majority of patients received cooperative radical treatment and were suitable for mouth bites. In the third group, DSPS was aligned within 2 mm in 89% of the population.

The DSPS showed more vertical (ANT-POST) improvements in the lower C-spine, whereas the lateral shifts were quite stable in all the groups (Figure 5). Using CIS, 86.5% of the population achieved alignment within 2 mm, whereas with NIS, this figure increased to 98%. This high alignment probability might be ascribed to a lower number of lymph node cases in the first and second groups. In the DSPS group, nearly 91% of patients attained alignment within 2 mm. As shown in Figure 6, the vertical shift was unstable with CIS due to a lack of properly-sized headrests (only one standard) and mouth bite. As a result, only 72% of the population attained alignment within 2 mm of an AP shift. In the NIS group, 99.4% of the population had alignment within 2 mm. However, this shift was not stable below C5. The DSPS shell possessed more stability in the lower C-spine, although the graph showed that 92.5% of the population achieved alignment within 2 mm. Overall, the AP shift throughout the spine was stable, and the oncologist gave the same margins from the head until C7. In this study, we reported an advantage of DSPS over customized headrests for head-and-neck cases, with DSPS nicely stabilizing the neck curvature. In addition, the residual shift in the lower neck area was less in cases with lower neck fields at the level of C7.

4. DISCUSSION

The Rapidarc technique provides the fastest radiation delivery, achieving better sparing of OARs, and more uniform and conformal dose distributions to the target volumes, thanks to continuous modulation of multi-leaf collimators (MLC), field shape, fluence rate, gantry rotation speed, and collimator angle [30].

One of the major factors affecting the accuracy of treatment was the patient setup error. Hence, the use of an immobilization device is imperative [22]. The immobilization device must provide adequate rigidity to ensure maximum

immobilization while providing sufficient comfort to ensure patient compliance [31]. Several comparative studies [32–38], using 2D kV and 3D cone beam CT images, reported the addition of accessories to thermoplastic-based devices to achieve more rigid immobilization. Comparing our results to those of other studies was difficult because most of these studies used different types of masks, mouth bites, or customized headrests. Random setup error refers to the interfraction variation of a patient's setup from day to day and can be of different values or in a different direction [17,39]. The random error represents the error distribution around the systematic error [17]. In this study, online correction was applied, the isocenter was re-marked on the mask on the 1st day, and CBCTs were excluded from the data on the 1st day. Therefore, systematic error was neglected. Based on the results of this study, approximately 90% of patients achieved alignment within a 2 mm shift in all x, y, and z directions. The current DSPS system provides better results in patients with lymph node involvement.

Although fixing the jaw can achieve a great gain in immobilizing the head, jaw fixation devices can be complicated and will suit only cooperative patients because it requires a tight bite from the patient throughout the session [40]. A simple bite block that can be attached to the thermoplastic mask can achieve desirable jaw fixation with minimum discomfort to the patient [41]. The mouth bite must conform tightly to the patient's dental impression to reproduce a perfect fit when re-positioned daily for better performance. It should be noted that the mouth bite used in our department has room for dislocation in the patient's mouth (Figure 7). In the future, it can be improved by filling the mouth bite piece with a dental material. We used a customized wax tongue depressor for the oral cavity/buccal mucosa.

However, mouthpieces may only be used for patients with good dental health. Disadvantages associated with the addition of a mouthpiece should be taken into account, such as the possible increase of mucosal reaction inside the mouth [42]. Moreover, proper cleaning and disinfection between sessions must be carried out without causing erosion of the mouthpiece [43]. All patients tolerated the mouth bite well as it was tasteless and odorless. However, some patients temporarily felt uncomfortable with the initial warmth of the mouth bite. Only a few patients with diseases in the oral cavity had difficulty tolerating the mouth bite at the end of the treatment due to the mucosal reaction of radiation treatment. Gagging reflection was witnessed only in one patient.

The standard headrest used in our department was only curved in the SI direction, leaving a gap between the patient's head and the mask on both sides of the head. These remaining gaps leave room for the mal-position and rotation of the head in both the lateral and longitudinal directions [22]. Other types

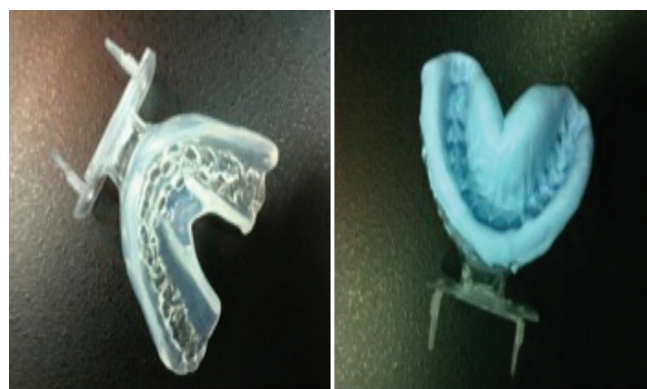

Figure 7. Precise mouth bites with and without the dental material filling. <https://ngha.med.sa/English/MedicalCities/Jeddah/MedDepartments/PNOC> [44].

of commercially available standard headrests are curved in two directions (SI and RL), which renders it difficult to find a good fit for patients of different sizes and neck lengths. In addition, standard headrests are composed of soft, pliable materials designed to enhance patient comfort. As a result, these materials undergo compression in response to the applied biomechanical load from the patient's body. The individually customized headrest outperforms the standard headrest by conforming to the gaps and curvatures of the head-and-neck region, giving full support over a larger area of the head-and-neck in both the SI and RL directions, effectively restricting head movement along these two axes. However, care should be taken when molding the customized headrest around the patient's head. Depending on the size of the patient's head, the customized headrest might bulge out laterally, superiorly, or under the patient's neck, creating an additional gap.

Although the gain in the setup accuracy was noticeable, adding the mouth bite and customized headrest to the immobilization system significantly increased the treatment cost. However, the DSPS technology showed good results in the head-and-neck. Nonetheless, further improvements are needed for the posterior shell because it takes a long time to become rigid in patients and a long time in a hot water bath. None of these accessories can be re-used for hygiene reasons. The manufacturing of additional immobilization accessories added at least 15 min of extra time to the CT simulation session. However, repositioning the accessories in the treatment room daily took no more than a few seconds.

The lower neck immobilization did not benefit from the NIS because the residual shifts did not show a significant improvement. Residual shifts were measured manually and subsequently subject to operator judgment [22]. The DSPS immobilization system showed greater accuracy with respect to the C-spine compared with the new immobilization. This study has several limitations. First, although we included

189 patients, we did not stratify them by key clinical factors such as gender, age, or tumor location, focusing solely on the type of immobilization device used. This absence of detailed grouping may influence the robustness of our conclusions, potentially limiting the applicability of the findings across diverse patient profiles. In addition, the study's outcomes may have been influenced by the disproportionately high number of nasopharyngeal cases, particularly within the DSPS group. This overrepresentation may have skewed the outcomes, affecting the overall generalizability of our findings.

5. CONCLUSION

It is essential to evaluate the current practice in radiation therapy to identify areas of potential improvement. This task has become easier with the new technologies available in the field of radiation therapy, such as IGRT. This study compared the online and offline alignment shifts for head-and-neck cases for three immobilization systems. Our findings provided strong evidence to confidently reject the null hypothesis. The data clearly demonstrated that the addition of a mouth bite and a customized headrest not only effectively limited head rotation but also stabilized neck curvature and significantly minimized the displacement of the head-and-neck. These results underscore the value of these modifications in enhancing patient stability during treatment. For RapidArc cases with a margin of 2–3 mm, the new system is highly recommended. However, immobilization of the lower neck area using a DSPS immobilization device for the shoulder area is very helpful for patient alignment.

ACKNOWLEDGMENTS

None.

FUNDING

None.

CONFLICT OF INTEREST

The authors declare no conflict of interest.

AUTHOR CONTRIBUTIONS

Conceptualization: Noor Mail, Batoor Khan, Majed Alghamdi, Suliman M. Alghamdi

Investigation: Khalid M. Alshamrani, Rab Nawaz Lodhi, Eman Khawandanh, Amani Saleem, Mohammed Nadershah; Majid S. Althaqafy, Ahmed Subahi

Methodology: Noor Mail, Khalid M. Alshamrani, Batoor Khan, Majed Alghamdi, Suliman M. Alghamdi

Writing – original draft: All authors

Writing – review & editing: Noor Mail, Khalid M. Alshamrani, Batoor Khan, Majed Alghamdi, Suliman M. Alghamdi

ETHICS APPROVAL AND CONSENT TO PARTICIPATE

The study was approved by the ethics committee (approval no.: SP21J/095/03) at the KAIMRC, ensuring that the research met ethical standards, including those related to data protection.

CONSENT FOR PUBLICATION

Informed consent was obtained from the study participants before study commencement, and the guidelines outlined in the Declaration of Helsinki were followed.

AVAILABILITY OF DATA

The data that support the findings of this study are not openly available due to reasons of sensitivity and are available from the corresponding author upon reasonable request.

REFERENCES

1. Malicki J. The importance of accurate treatment planning, delivery, and dose verification. *Rep Pr Oncol Radiother.* 2012;17:63-65. doi: 10.1016/j.rpor.2012.02.001
2. Hansen CR, Christiansen RL, Nielsen TB, Bertelsen AS, Johansen J, Brink C. Comparison of three immobilisation systems for radiation therapy in head and neck cancer. *Acta Oncol.* 2014;53:423-427. doi: 10.3109/0284186x.2013.813966
3. Beltran C, Krasin MJ, Merchant TE. Inter- and intrafractional positional uncertainties in pediatric radiotherapy patients with brain and head and neck tumors. *Int J Radiat Oncol Biol Phys.* 2011;79:1266-1274. doi: 10.1016/j.ijrobp.2009.12.057
4. Boda-Heggemann J, Walter C, Rahn A, *et al.* Repositioning accuracy of two different mask systems-3D revisited: Comparison using true 3D/3D matching with cone-beam CT. *Int J Radiat Oncol Biol Phys.* 2006;66:1568-1575. doi: 10.1016/j.ijrobp.2006.08.054
5. Chen AM, Yu Y, Daly ME, Farwell DG, Benedict SH, Purdy JA. Long-term experience with reduced planning target volume margins and intensity-modulated radiotherapy with daily image-guidance for head and neck cancer. *Head Neck.* 2014;36:1766-1772. doi: 10.1002/hed.23532
6. Graff P, Kirby N, Weinberg V, *et al.* The residual setup errors of different IGRT alignment procedures for head and neck IMRT and the resulting dosimetric impact. *Int J Radiat Oncol Biol Phys.* 2013;86:170-176. doi: 10.1016/j.ijrobp.2012.10.040
7. Castelli J, Simon A, Acosta O, *et al.* The role of imaging

- in adaptive radiotherapy for head and neck cancer. *IRBM*. 2014;35:33-40.
doi: 10.1016/j.irbm.2013.12.003
8. Giske K, Stoiber EM, Schwarz M, *et al.* Local setup errors in image-guided radiotherapy for head and neck cancer patients immobilized with a custom-made device. *Int J Radiat Oncol Biol Phys*. 2011;80:582-589.
doi: 10.1016/j.ijrobp.2010.07.1980
 9. Chen AM, Farwell DG, Luu Q, Donald PJ, Perks J, Purdy JA. Evaluation of the planning target volume in the treatment of head and neck cancer with intensity-modulated radiotherapy: What is the appropriate expansion margin in the setting of daily image guidance? *Int J Radiat Oncol Biol Phys*. 2011;81:943-949.
doi: 10.1016/j.ijrobp.2010.07.017
 10. Kung JS, Tran WT, Poon I, *et al.* Evaluation of the efficacy of rotational corrections for standard-fractionation head and neck image-guided radiotherapy. *Technol Cancer Res Treat*. 2019;18:1533033819853824.
doi: 10.1177/1533033819853824
 11. Anjanappa M, Rafi M, Bhasi S, *et al.* Setup uncertainties and PTV margins at different anatomical levels in intensity modulated radiotherapy for nasopharyngeal cancer. *Rep Pract Oncol Radiother*. 2017;22:396-401.
doi: 10.1016/j.rpor.2017.07.005
 12. Georg D, Bogner J, Dieckmann K, Pötter R. Is mask-based stereotactic head-and-neck fixation as precise as stereotactic head fixation for precision radiotherapy? *Int J Radiat Oncol Biol Phys*. 2006;66:S61-S66.
doi: 10.1016/j.ijrobp.2006.05.075
 13. Gilbeau L, Octave-Prignot M, Loncol T, Renard L, Scalliet P, Grégoire V. Comparison of setup accuracy of three different thermoplastic masks for the treatment of brain and head and neck tumors. *Radiother Oncol*. 2001;58:155-162.
doi: 10.1016/s0167-8140(00)00280-2
 14. Hong TS, Tomé WA, Chappell RJ, Chinnaiyan P, Mehta MP, Harari PM. The impact of daily setup variations on head-and-neck intensity-modulated radiation therapy. *Int J Radiat Oncol Biol Phys*. 2005;61:779-788.
doi: 10.1016/j.ijrobp.2004.07.696
 15. Jones D. ICRU report 50-prescribing, recording and reporting photon beam therapy. *Med Phys*. 1994;21:833-834.
doi: 10.1118/1.597396
 16. Landberg T, Chavaudra J, Dobbs J, *et al.* Report 62. *J Int Comm Radiat Units Meas*. 1999;os32:NP.
doi: 10.1093/jicru/os32.1.report62
 17. Van Herk M. Errors and margins in radiotherapy. *Semin Radiat Oncol*. 2004;14:52-64.
doi: 10.1053/j.semradonc.2003.10.003
 18. Yoram F, Dharsee N, Mkoka DA, Maunda K, Kisukari JD. Radiation therapists' perceptions of thermoplastic mask use for head and neck cancer patients undergoing radiotherapy at Ocean Road Cancer Institute in Tanzania: A qualitative study. *PLoS One*. 2023;18:e0282160.
doi: 10.1371/journal.pone.0282160
 19. Mesías MC, Boda-Heggemann J, Thoelking J, Lohr F, Wenz F, Wertz H. Quantification and assessment of interfraction setup errors based on cone beam CT and determination of safety margins for radiotherapy. *PLoS One*. 2016;11:e0150326.
doi: 10.1371/journal.pone.0150326
 20. Sharp L, Lewin F, Johansson H, Payne D, Gerhardsson A, Rutqvist LE. Randomized trial on two types of thermoplastic masks for patient immobilization during radiation therapy for head-and-neck cancer. *Int J Radiat Oncol Biol Phys*. 2005;61:250-256.
doi: 10.1016/j.ijrobp.2004.04.047
 21. Bhide S, Nutting C. Recent advances in radiotherapy. *BMC Med*. 2010;8:25.
doi: 10.1186/1741-7015-8-25
 22. Leech M, Coffey M, Mast M, *et al.* ESTRO ACROP guidelines for positioning, immobilisation and position verification of head and neck patients for radiation therapists. *Tech Innov Patient Support Radiat Oncol*. 2017;1:1-7.
doi: 10.1016/j.tipsro.2016.12.001
 23. Fu C, Ma C, Shang D, *et al.* Geometric accuracy evaluation of a six-degree-of-freedom (6-DoF) couch with cone beam computed tomography (CBCT) using a phantom and correlation study of the position errors in pelvic tumor radiotherapy. *Transl Cancer Res*. 2020;9:6005-6012.
doi: 10.21037/tcr-20-1528
 24. Divneet M, Quoc-Anh H, Betsy W, *et al.* Comparison of two thermoplastic immobilization mask systems in daily volumetric image guided radiation therapy for head and neck cancers. *Biomed Phys Eng Express*. 2018;4:055007.
doi: 10.1088/2057-1976/aad574
 25. Prescribing, recording, and reporting photon-beam intensity-modulated radiation therapy (IMRT). *JICRU*. 2010;10:1-3.
doi: 10.1093/jicru_ndq002
 26. Islam MK, Purdie TG, Norrlinger BD, *et al.* Patient dose from kilovoltage cone beam computed tomography imaging in radiation therapy. *Med Phys*. 2006;33:1573-1582.
doi: 10.1118/1.2198169
 27. Kim S, Akpati HC, Kielbasa JE, *et al.* Evaluation of intrafraction patient movement for CNS and head & neck IMRT. *Med Phys*. 2004;31:500-506.
doi: 10.1118/1.1644641
 28. Humphreys M, Urbano MTG, Mubata C, *et al.* Assessment of a customised immobilisation system for head and neck IMRT using electronic portal imaging. *Radiother Oncol*. 2005;77:39-44.
doi: 10.1016/j.radonc.2005.06.039
 29. *IR. Sample Size Calculator by Raosoft Inc*; n.d. Available from: <https://www.raosoft.com/samplesize.html> [Last accessed on 2023 Aug 02].
 30. Otto K. Volumetric modulated arc therapy: IMRT in a single gantry arc. *Med Phys*. 2008;35:310-317.
doi: 10.1118/1.2818738
 31. Mail N, Al-Ghamdi SM, Chantel C, Sedhu F, Rana A, Saoudi A. Customized double-shell immobilization device combined with VMAT radiation treatment of basosquamous cell carcinoma of the scalp. *J Appl Clin Méd Phys*. 2019;20:84-93.
doi: 10.1002/acm2.12536
 32. Li H, Zhu XR, Zhang L, *et al.* Comparison of 2D radiographic images and 3D cone beam computed tomography for positioning head-and-neck radiotherapy patients. *Int J Radiat Oncol Biol Phys*. 2008;71:916-925.

- doi: 10.1016/j.ijrobp.2008.01.008
33. Oita M, Ohmori K, Obinata K, *et al.* Uncertainty in treatment of head-and-neck tumors by use of intraoral mouthpiece and embedded fiducials. *Int J Radiat Oncol Biol Phys.* 2006;64:1581-1588.
doi: 10.1016/j.ijrobp.2005.11.038
 34. Rotondo RL, Sultanem K, Lavoie I, Skelly J, Raymond L. Comparison of repositioning accuracy of two commercially available immobilization systems for treatment of head-and-neck tumors using simulation computed tomography imaging. *Int J Radiat Oncol Biol Phys.* 2008;70:1389-1396.
doi: 10.1016/j.ijrobp.2007.08.035
 35. Siebers JV, Keall PJ, Wu Q, Williamson JF, Schmidt-Ullrich RK. Effect of patient setup errors on simultaneously integrated boost head and neck IMRT treatment plans. *Int J Radiat Oncol Biol Phys.* 2005;63:422-433.
doi: 10.1016/j.ijrobp.2005.02.029
 36. Suzuki M, Nishimura Y, Nakamatsu K, *et al.* Analysis of interfractional set-up errors and intrafractional organ motions during IMRT for head and neck tumors to define an appropriate planning target volume (PTV)- and planning organs at risk volume (PRV)-margins. *Radiother Oncol.* 2006;78:283-290.
doi: 10.1016/j.radonc.2006.03.006
 37. Wang J, Bai S, Chen N, *et al.* The clinical feasibility and effect of online cone beam computer tomography-guided intensity-modulated radiotherapy for nasopharyngeal cancer. *Radiother Oncol.* 2009;90:221-227.
doi: 10.1016/j.radonc.2008.08.017
 38. Chen L, Peng YL, Gu SY, *et al.* Dosimetric effects of head and neck immobilization devices on multi-field intensity modulated radiation therapy for nasopharyngeal carcinoma. *J Cancer.* 2018;9:2443-2450.
doi: 10.7150/jca.24887
 39. Giżyńska MK, Kukołowicz PF, Heijmen BJM. Coping with interfraction time trends in tumor setup. *Méd Phys.* 2020;47:331-341.
doi: 10.1002/mp.13919
 40. Kawashita Y, Soutome S, Umeda M, Saito T. Oral management strategies for radiotherapy of head and neck cancer. *Jpn Dent Sci Rev.* 2020;56:62-67.
doi: 10.1016/j.jdsr.2020.02.001
 41. Cleland S, Crowe SB, Chan P, *et al.* Development of a customisable 3D-printed intra-oral stent for head-and-neck radiotherapy. *Tech Innov Patient Support Radiat Oncol.* 2022;23:1-7.
doi: 10.1016/j.tipsro.2022.06.001
 42. Devi S, Singh N. Dental care during and after radiotherapy in head and neck cancer. *Natl J Maxillofac Surg.* 2014;5:117-125.
doi: 10.4103/0975-5950.154812
 43. Tolentino ES, Centurion BS, Ferreira LHC, Souza AP, Damante JH, Rubira-Bullen IRF. Oral adverse effects of head and neck radiotherapy: Literature review and suggestion of a clinical oral care guideline for irradiated patients. *J Appl Oral Sci.* 2011;19:448-454.
doi: 10.1590/s1678-77572011000500003
 44. Radiation Oncology Section, Princess Noorah Oncology Center (PNOC). Jeddah, Saudi Arabia: Ministry of the National Guard - Health Affairs. Available from: <https://ngha.med.sa/english/medicalcities/jeddah/meddepartments/pnoc> [Last accessed on 2024 Jul 15].



This article is an open access article distributed under the terms and conditions of the Creative Commons Attribution 4.0 International License (<https://creativecommons.org/licenses/by/4.0/>)