

Oncological and functional outcomes and complications of robotic intracorporeal Studer orthotopic neobladder: A single-center retrospective study

Qiang Cheng^{1,2,3†}, Yin Lu^{1,3,4†}, Bin Jiang^{1,3,4†}, Qing Ai^{1,3}, Fan Gao^{1,3,4}, Xupeng Zhao^{1,3,4}, Jinlu Tang^{1,2,3}, Yi Feng^{1,2,3}, Wenfeng Gao^{1,3,4}, and Hongzhao Li^{1*}

¹Department of Urology, Chinese People's Liberation Army General Hospital, Beijing 100039, China

²Chinese People's Liberation Army Medical School, Beijing 100853, China

³Senior Department of Urology, The Third Medical Center of People's Liberation Army General Hospital, Beijing 100039, China

⁴School of Medicine, Nankai University, Tianjin 300071, China

[†]These authors contributed equally to this work.

Abstract

Background: Robotic intracorporeal Studer orthotopic neobladder (RISON) is a complex procedure for bladder reconstruction. **Objective:** This study aimed to retrospectively examine the oncological/functional outcomes, and complications of RISON at a single center. **Methods:** Baseline data and perioperative results of patients who received RISON between March 2018 and December 2022 were analyzed. Sixty-two cases (60 males, 2 females), with a mean age of 56.79 ± 9.12 years, were included in the study. Follow-up data regarding RISON's therapeutic effects, including tumor outcomes, neobladder capacity, continence, and complications, were collected. **Results:** All patients underwent the procedure without conversion to open surgery or changes in urinary diversion. The mean operative time lasted 379.2 ± 88.8 min, with a median blood loss of 200 mL (range: 100–300 mL). Indwelling time of the Ryles tube was 3.78 ± 2.23 days, and post-operative hospital stay was 10 days (range: 8–12 days). Pathological examination showed 87.1% (54/62) of cases had T2N0M0 tumors. A mean of 17.42 ± 8.03 lymph nodes were dissected, with three cases developing lymph node metastasis. Short-term complications (within 30 days) occurred in 51.9% of patients, while long-term complications (after 30 days) were found in 51.9% of patients. The mean neobladder volume measured 344.31 ± 147.00 mL. Daytime continence was achieved in 88.2% of patients, and night-time continence was attained in 39.2%. The average night-time urinary frequency was 2.78 ± 1.55 times, with 1.9 urine pads used on average. Follow-up duration ranged from 27 to 73 months, with a median time of 52.5 months. Five patients died of tumor metastasis, spreading to bone, liver, lung, brain, or lymph nodes. The 36- and 60-month cumulative recurrence-free survival rates were 96.3% and 87.4%, respectively. The 36- and 60-month cumulative overall survival rates were 96.3% and 90.4%, respectively. **Conclusion:** Clinically, RISON is a safe and feasible procedure with excellent oncological and functional outcomes, showing promise for widespread application.

Keywords: Intracorporeal Studer orthotopic neobladder, Robotic surgeries, Oncologic outcomes, Functional outcomes, Complications

1. Introduction

Bladder cancer represents the 10th most common cancer across the globe, with approximately 573,000 new cases and 213,000 deaths in 2020.¹ While the ileal conduit remains the most commonly used form of urinary diversion globally, there has been a notable increase in the adoption of orthotopic neobladder in recent years.² Radical cystectomy is the standard treatment for muscle-invasive bladder cancer (MIBC) and high-risk recurrent non-muscle-invasive bladder cancer (NMIBC).³ Following a radical cystectomy, a urinary diversion is required, with common types including ileal conduit, orthotopic neobladder, and cutaneous ureterostomy.^{4,5} With

***Corresponding author:**
Hongzhao Li (urolancet@126.com)

This is an open-access article under the terms of the Creative Commons Attribution License, which permits use, distribution, and reproduction in any medium, provided the original work is properly cited.

© 2025 Bladder published by POL Scientific

Submitted: 02 August 2024; Revision received: 09 October 2024;
Accepted: 21 November 2024; Published: 09 January 2025

How to cite this article: Cheng Q, Lu Y, Jiang B, *et al.* Oncological and functional outcomes and complications of robotic intracorporeal Studer orthotopic neobladder: A single-center retrospective study. *Bladder*. 2025;12(1):e21200029. DOI: 10.14440/bladder.2024.0025

advancements in robotic surgery technology and the growing emphasis on rehabilitation, intracorporeal urinary diversion has been gaining widespread application. Data from the International Robotic Cystectomy Consortium indicate that the utilization rate of intracorporeal urinary diversion increasing from 9% in 2005 to 97% in 2015, with the adoption rate of orthotopic neobladder rising from 7% to 17%.⁶ Randomized controlled trials have demonstrated that, compared to traditional open surgery, total laparoscopic urinary diversion results in comparable oncological outcomes but reduces the transfusion rate and offers certain quality-of-life benefits.^{7,8} In this study, we retrospectively reviewed the data from a single-center, prospective study of robotic intracorporeal Studer orthotopic neobladder (RISON). The efficacy of the procedure was evaluated with respect to oncological and functional outcomes, as well as complications. Oncological outcomes included post-operative pathology and recurrence rates, and functional outcomes were assessed based on neobladder capacity and daytime continence. Complications were evaluated and graded using the Clavien-Dindo classification system.

2. Materials and methods

2.1. Study population

RISON was performed on 62 patients by the same surgeon (Dr. HZ Li) from March 2018 to December 2022 at the General Hospital of the People's Liberation Army (PLA), Beijing, China. A retrospective analysis was conducted using a prospectively maintained database of these patients. The study was approved by the Ethics Committee of the Chinese PLA General Hospital Third Medical Centre (approval number: 2018-P2-081-04). All patients provided written informed consent, and all relevant details were discussed with and consented to by the patients. Patients with missing data were excluded from the study. A total of 52 patients were effectively followed up.

2.2. Indications and perioperative care

All surgical procedures were performed in accordance with the guidelines for patients with non-metastatic MIBC, unresponsive NMIBC, and recurrence following bladder-sparing therapy.³ Nerve-sparing radical cystectomy was performed in patients who were sexually active and desired to conserve sexual function. The specific steps of the nerve-sparing technique are detailed in our previous study.⁹ Perioperative management followed the principles of enhanced recovery, including pre-operative counseling, early post-operative mobilization, and chewing gum on the first post-operative day.^{10,11} All relevant information was recorded in detail, including age, body mass index (BMI), whether patients received neoadjuvant chemotherapy, duration of indwelling Ryles tube, operative time, blood loss, post-operative hospital stay, tumor outcomes, neobladder capacity,

incontinence, and occurrence of complications. Patients with locally advanced disease or positive surgical margins were given adjuvant chemotherapy.

2.3. Follow-up

Follow-up was conducted in accordance with the National Comprehensive Cancer Network/European Association of Urology (EAU) guidelines. Patients were recommended to undergo a computed tomography scan every 3–4 months during the 1st year, and then every 6 months until the 3rd year.³ We followed the EAU's recommendations on the appropriate use of social media and maintained contact with each patient for rehabilitation and follow-up through outpatient visits, telephone, and WeChat.¹² Daytime continence was defined as the ability to stay dry during the day without the need for urinary pads, while night-time continence was measured by the number of pads used. Night-time urination was defined as the number of times a person urinated between 22:00 and 06:00. All post-operative complications (early [≤ 30 days] and late [>30 days]) were graded using the Clavien–Dindo classification system, and the details of the complications were clearly recorded.

2.4. Statistical analysis

Continuous data are presented as median and interquartile range, while categorical data are expressed as frequencies and proportions. The Kaplan–Meier method was used to depict recurrence-free survival (RFS) and overall survival (OS). Data analysis was performed using IBM SPSS Statistics 26.0 (United States).

3. Results

All patients underwent RISON without conversion to open surgery or changes in urinary diversion. The cohort included 60 males and two females, with a mean age of 56.79 ± 9.12 years and a BMI of 25.31 ± 3.03 kg/m². Neoadjuvant platinum-based chemotherapy was administered in 11 out of the 62 patients. The mean operative time lasted for 379.2 ± 88.8 min, with a median blood loss of 200 mL (range: 100–300 mL). The indwelling time for the Ryles tube was 3.78 ± 2.23 days, and the post-operative hospitalization duration was 10 days (range: 8–12 days). Post-operative pathological results revealed that 54 (87.1%) cases were staged T2N0M0. Of the 62 cases, three had a positive surgical margin, and one was diagnosed with incidental prostate cancer. A mean of 17.42 ± 8.03 lymph nodes were dissected, and three cases had confirmed lymph node metastasis (Table 1). Short-term (within 30 days) complications occurred in 51.9% (27/52) of patients, including Clavien Grade I in eight cases, Grade II in 15 cases, and Grade III in four cases. Long-term (beyond 30 days) complications also occurred in 51.9% (27/52) patients, with Clavien Grade I in 16 cases,

Table 1. Baseline and perioperative data

Characteristics	Value
Total, n (%)	62 (100)
Male	60 (96.8)
Female	2 (3.2)
Age, yr, mean±SD	56.79±9.12
BMI, kg/m ² , mean±SD	25.31±3.03
Neoadjuvant chemotherapy, n (%)	
Presence	11 (17.8)
Absence	51 (82.2)
Pre-operative continence	Normal
Operation time, mins, mean±SD	379.2±88.8
Indwelling Ryles tube, days, mean±SD	3.78±2.23
Post-operative hospital stay, days, median (IQR)	10 (8–12)
pT stage, n (%)	
T0, Tis	3 (4.8)
T1	15 (24.2)
T2	36 (58.1)
T3	4 (6.5)
T4	4 (6.5)
Positive surgical margin, n (%)	3 (4.8)
Incidental prostate cancer, n (%)	1 (1.6)
pN stage, n (%)	
0	0
1	3 (4.8)
2	0
Number of lymph nodes, n, Mean±SD	17.42±8.03

Abbreviations: BMI: Body mass index; IQR: Interquartile range; mins: Minutes; pN: Pathological nodal status; pT: Pathological tumor extent; SD: Standard deviation; yr: Years.

Grade II in nine cases, and Grade III in two cases (Table 2). One patient underwent ileal conduit surgery 13 months postoperatively due to recurrent urinary tract and abdominal infections, hydronephrosis, and ascites. Another female patient developed incontinence 3 months after surgery and required self-catheterization at home. Excluding the patient who received ileal conduit diversion and the one requiring self-catheterization, the average bladder capacity of the remaining patients was 344.3 ± 47.00 mL. Daytime continence afflicted 88.2% (45/51) of patients, while 39.2% (20/51) maintained night-time continence. The average night-time urinary frequency was 2.78 ± 1.55 times, with patients using an average of 1.9 urine pads. Forty-five patients had night-time urinary intervals of <180 min (Table 3). The follow-up period ranged from 27 to 73 months, with a median of 52.5 months. Recurrence took place in two patients at 19 and 21 months post-surgery, at the ureter-neobladder junction and in the pelvic lymph nodes, respectively. Seven patients developed metastasis postoperatively. Five patients (four males and one female) died from tumor metastasis at 36, 36, 38, 41, and 43 months after surgery. Metastatic sites included the bone, liver, lung, brain, and lymph nodes. The 36- and 60-month cumulative RFS rates were 96.3% and 87.4%, respectively.

Table 2. Complication outcomes

Complications	Number	Grade	Treatment
Early (≤30 days), n (%)	27 (51.9)	-	-
Infectious complications	15 (28.8)	II	Intravenous antibiotics
Gastrointestinal complications	5 (9.6)	I	Gastrointestinal decompression
Ascites	4 (7.7)	III	Abdominocentesis or surgery
Other complications	3 (5.8)	I	Observation
Late (>30 days), n (%)	27 (51.9)	-	-
Infectious complications	9 (17.3)	II	Oral or intravenous antibiotics
Gastrointestinal complications	4 (7.7)	I	Gastrointestinal decompression
Hernia	3 (5.8)	I	Observation
Hernia	1 (1.9)	III	Surgery
Hydronephrosis	8 (15.4)	I	Observation
Ascites	1 (1.9)	III	Surgery
Dysuria	1 (3.0)	I	Catheterization

Note: Continence is defined as the absence of the need for pads.

Table 3. Continence outcomes

Characteristics	Value
Total, n (%)	51 (82.3)
Bladder volume, mL, mean±SD	344.31±147.00
Day continence, n (%)	45 (88.2)
Night continence, n (%)	20 (39.2)
Night urine, n, mean±SD	2.78±1.55
Urine pads, n	1.9
Night-time urinary intervals<180 min, n (%)	45 (88.2)

Abbreviation: SD: Standard deviation.

The 36- and 60-month cumulative OS rates were 96.3% and 90.4%, respectively (Figures 1 and 2).

4. Discussion

Bladder cancer is typically classified into NMIBC and MIBC. The optimal treatment for NMIBC involves complete resection of all visible lesions within the bladder, followed by intravesical instillation or early radical cystectomy based on risk stratification.¹³ For MIBC, radical cystectomy is widely regarded as the standard treatment, as endorsed by guidelines from the EAU, the American Urological Association, the American Society of Clinical Oncology, and the American Society for Radiation Oncology.¹⁴ After radical cystectomy, a urinary diversion is necessary, and its choice must consider both complications and tumor characteristics.¹⁵ Pre-operative diagnosis of infiltrative urethral cancer is considered a contraindication for neobladder reconstruction following bladder resection.¹⁶ Relative contraindications for an orthotopic neobladder include severe incontinence related to the urethral sphincter, complex urethral strictures, and high-dose pre-operative radiation therapy.⁸ Our center has also conducted research on and clinically used robotic bladder cancer resection and orthotopic neobladder surgery.

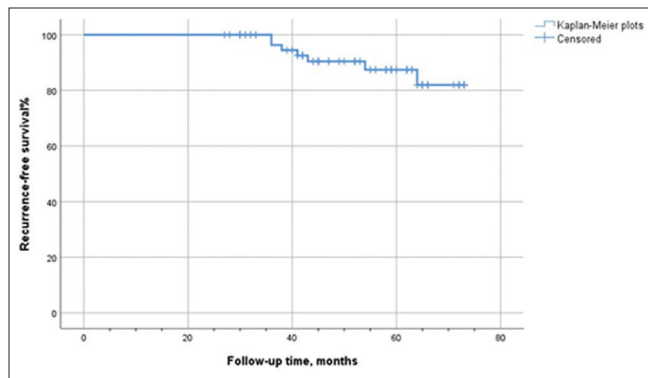


Figure 1. Kaplan–Meier plots of recurrence-free survival

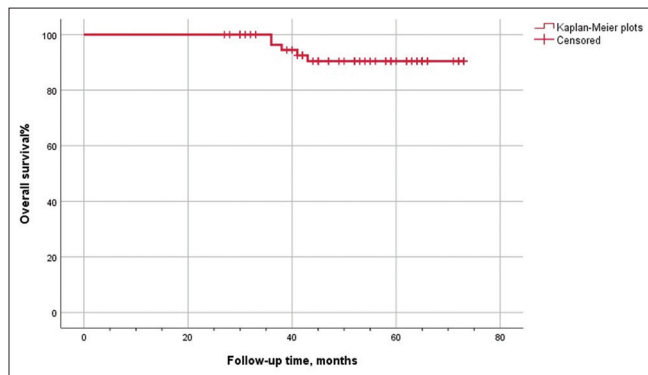


Figure 2. Kaplan–Meier plots of overall survival

Due to the complexity and high technical demands, RISON was initially restricted to large, high-volume medical institutions. However, with the advancement and widespread introduction of the technology, intracorporeal neobladder diversion has been shown to yield satisfactory outcomes, in line with results from contemporary open surgical series.¹⁷ Furthermore, intracorporeal urinary diversion offers comparable complication rates, superior perioperative outcomes, and similar oncological outcomes compared to extracorporeal urinary diversion.^{18–21}

Various techniques for intracorporeal neobladder reconstruction have been described, including the Karolinska-modified Studer neobladder,²² University of Southern California-modified Studer neobladder,²³ pyramid pouch,²⁴ Y-pouch,²⁵ and Vescica Ileale Padovana.²⁶ The Studer orthotopic bladder is highly operable and offers advantages in terms of orthotopic bladder capacity and urinary control.^{27,28} Based on our experience and a review of previous cases, we have summarized several key technical considerations: (i) if the patient's BMI is $<24 \text{ kg/m}^2$, we recommend positioning all trocars 1–2 cm to the cephalic side; (ii) strengthening the posterior urethral wall and Denonvilliers' fascia with barbed sutures can lower the tension at the urethra-neobladder neck anastomosis and enhance the structural support around urethra, improving continence postoperatively; (iii) early anastomosis of the urethra and neobladder neck facilitates precision surgery

under optimal visualization, maximizes urethral length, and provides additional fixation points at the distal end, thereby reducing bowel mobility and making intestinal management easier. In addition, this approach allows for more effective adjustment of the neobladder shape to morphologically fit the pelvic cavity; (iv) selecting the appropriate staple height and length is essential to ensure perpendicularity to the long axis of the intestine, thereby ensuring adequate mesentery attachment at the end of the intestine and preserving the blood supply to the bowel; (v) when suturing the neobladder, stitching the serosal and muscular layers together helps shape the bladder in a varus configuration, effectively preventing urine leakage. Proper positioning of the suture line improves the bladder shape, provides appropriate traction, and simplifies suturing, thereby reducing operative time; (vi) a no-tension, mucosa-to-mucosa anastomosis using a no-touch technique ensures optimal ureteral viability; (vii) since the procedure is entirely intracorporeal, the exposure time of the intestine is minimized, resulting in a faster functional recovery and allowing for valuable time for adjuvant chemotherapy, when needed.

The main challenges associated with this procedure include: (i) the surgical technique is complicated, requiring a relatively protracted operation time, particularly in the early stages. Surgeons must possess extensive experience in robotic surgery to perform the procedure effectively; (ii) the learning curve is steep, with a higher incidence of intraoperative complications observed during the early phase of the learning process; (iii) the procedure necessitates use of specialized surgical instruments, which can pose added financial burden on patients; (iv) post-operative care involves effective communication with patients and thorough rehabilitation guidance and follow-up. In addition, pre-operative imaging cannot accurately stage bladder tumors: The diagnostic accuracy for tumor outward growth ranges from 55 to 92%, and the sensitivity for detecting lymph node metastasis based solely on size is 48–87%.^{29–31} F-18 fluorodeoxyglucose positron emission tomography/computed tomography has been used to detect lymph node metastasis in bladder cancer, with a sensitivity of 0.57 (95% confidence interval: 0.49–0.64) and specificity of 0.92 (95% confidence interval: 0.87–0.95).³² Due to China's healthcare insurance policies, out-of-pocket expenses for the same procedure may vary among patients, making it essential to discuss the surgical costs categorically. Given the small sample size of this study, the economic impact of RISON was not analyzed. Although robotic-assisted radical cystectomy (RARC) did not demonstrate a financial advantage over its traditional counterparts, it has been found to be associated with reduced overall perioperative blood transfusion rates compared to open surgery, with no significant differences in perioperative and post-operative complications or 3-year oncological outcomes between them.³³ Consequently, the use of RARC plus total

intracorporeal urinary diversion may present an unnecessary economic burden on patients and the benefits and risks should be carefully weighed. Therefore, patients for this procedure should be meticulously selected.

With surgeons gaining experience, intracorporeal neobladder diversion is incrementally being adopted and has shown potential benefits, including reduced fluid and blood loss, less pain, smaller surgical incisions, expedited recovery of bowel function, and fewer anastomotic strictures.³⁴ In our study, the early complication rate (51.9%) was higher than 30–31.4% reported in the literature, and the late complication rate (51.9%) was also greater than those in previous studies.^{17,24} This finding might be attributed to the early cases being part of the learning curve,³⁵ where patients treated early tend to experience worse perioperative and functional outcomes.³⁶ However, after standardization of the procedure, significant improvements were noted in complication rates, hospital stays, and recovery of daytime continence. Wei *et al.*³⁷ compared an enhanced recovery after surgery (ERAS) group with non-ERAS groups and found that ERAS implementation was associated with fewer complications (29.4% vs. 64.5%, $P = 0.018$), shorter time to first flatus (2 vs. 3 days, $P = 0.016$), and earlier initiation of liquid diet (2 vs. 4 days, $P < 0.001$) in intracorporeal urinary diversion. Furthermore, the nerve-sparing technique has proven to be advantageous in terms of both continence and erectile function in orthotopic neobladder procedures.^{17,24,38,39} Our study preliminarily confirmed these findings, though further larger-sample studies and longer time follow-ups are warranted to provide more accurate evidence.

Kretschmer *et al.*⁴⁰ reported that, among 188 patients who underwent radical cystectomy and ileal orthotopic neobladder, good pre-operative Eastern Cooperative Oncology Group performance status (odds ratio 2.987, $P = 0.010$), retained sensation for bladder filling (odds ratio 6.462, $P = 0.003$), and the absence of pre-operative coronary heart disease (odds ratio 0.036, $P = 0.002$) were independent predictors of daytime continence.⁴⁰ However, there is a lack of standardized assessment methods for this outcome, as well as an absence of objective outcome measurements through questionnaires or assessments of urinary dynamics. Clifford *et al.*⁴¹ developed a validated questionnaire to evaluate continence following radical cystectomy and orthotopic neobladder, finding that continence improved significantly by 6 months and subsequently plateaued, with 92% of patients achieving daytime continence by 12–18 months. Satkunasivam *et al.*⁴² compared urodynamics, tumor outcomes, and health-related quality of life (HRQOL), concluding that patients with intracorporeal neobladder had excellent urodynamic results and comparable bladder cancer-specific HRQOL scores to those with extracorporeal neobladder. More recent evidence suggests that functional outcomes following RISON are

acceptable, but larger, prospective randomized trials are needed to confirm these findings.⁴³

Our study is subject to several limitations. The sample size was relatively small, and there might be some loss of data. In addition, the study data were from a single medical center, which might limit the generalizability of the results. Further research on nerve-sparing techniques in RISON could provide more compelling evidence of its efficacy. Moreover, the number of female patients in our study was very small.

5. Conclusion

RISON is an increasingly viable option for urinary diversion, offering advantages such as smaller incisions, reduced pain, fewer complications, and faster post-operative recovery compared to traditional open surgery. This technique has the potential to significantly improve the quality of life for patients following urinary diversion. The continued adoption of RISON is expected to gain momentum and further enhance patients' clinical outcomes and overall well-being.

Acknowledgments

None.

Funding

This work was supported by the National Key R&D Program of China (grant no. 2023YFC2507006 and 2022YFC3602900) and the Youth Independent Innovation Science Fund Support Project of People's Liberation Army (PLA) General Hospital (grant no. 22QNFC047).

Conflict of interest

The authors declare no conflicts of interest.

Author contributions

Conceptualization: Hongzhao Li

Data curation: Qiang Cheng, Yin Lu, Bin Jiang, Qing Ai, Fan Gao, Xupeng Zhao, Jinlu Tang, Yi Feng, Wenfeng Gao

Formal analysis: Qiang Cheng, Yin Lu, Bin Jiang, Qing Ai, Fan Gao, Jinlu Tang, Wenfeng Gao

Writing – original draft: Qiang Cheng, Yin Lu

Writing – review & editing: Hongzhao Li

Ethics approval and consent to participate

The study was approved by the Ethics Committee of the Third Medical Centre of Chinese PLA General Hospital. All patients provided written informed consent, and all relevant details were discussed with the patients before obtaining their consent. The ethical approval number is 2018-P2-081-04.

Consent for publication

All participants provided written informed consent, explicitly agreeing to the publication of their data as part of this study.

Availability of data

The data supporting the findings of this study are available from the corresponding author upon reasonable request.

References

1. Sung H, Ferlay J, Siegel RL, *et al.* Global Cancer Statistics 2020: GLOBOCAN estimates of incidence and mortality worldwide for 36 cancers in 185 countries. *CA Cancer J Clin.* 2021;71(3):209-249. doi: 10.3322/caac.21660
2. Tappero S, Dell'Oglio P, Cerruto MA, *et al.* Ileal conduit versus orthotopic neobladder urinary diversion in robot-assisted radical cystectomy: Results from a multi-institutional series. *Eur Urol Open Sci.* 2023;50:47-56. doi: 10.1016/j.euros.2023.01.009
3. Alfred Witjes J, Lebre T, Compérat EM, *et al.* Updated 2016 EAU guidelines on muscle-invasive and metastatic bladder cancer. *Eur Urol.* 2017;71(3):462-475. doi: 10.1016/j.eururo.2016.06.020
4. Lee RK, Abol-Enein H, Artibani W, *et al.* Urinary diversion after radical cystectomy for bladder cancer: Options, patient selection, and outcomes. *BJU Int.* 2014;113(1):11-23. doi: 10.1111/bju.12121
5. Perimenis P, Koliopanou E. Postoperative management and rehabilitation of patients receiving an ileal orthotopic bladder substitution. *Urol Nurs.* 2004;24(5):383-386.
6. Hussein AA, May PR, Jing Z, *et al.* Outcomes of intracorporeal urinary diversion after robot-assisted radical cystectomy: Results from the international robotic cystectomy consortium. *J Urol.* 2018;199(5):1302-1311. doi: 10.1016/j.juro.2017.12.045
7. Mastroianni R, Ferriero M, Tuderti G, *et al.* Open radical cystectomy versus robot-assisted radical cystectomy with intracorporeal urinary diversion: Early outcomes of a single-center randomized controlled trial. *J Urol.* 2022;207(5):982-992. doi: 10.1097/ju.0000000000002422
8. Mastroianni R, Tuderti G, Anceschi U, *et al.* Comparison of patient-reported health-related quality of life between open radical cystectomy and robot-assisted radical cystectomy with intracorporeal urinary diversion: Interim analysis of a randomised controlled trial. *Eur Urol Focus.* 2022;8(2):465-471. doi: 10.1016/j.euf.2021.03.002
9. Mastroianni R, Tuderti G, Ferriero M, *et al.* Robot-assisted radical cystectomy with totally intracorporeal urinary diversion versus open radical cystectomy: 3-year outcomes from a randomised controlled trial. *Eur Urol.* 2024;85(5):422-430. doi: 10.1016/j.eururo.2024.01.018
10. Cheng Q, Gu L, Chen W, *et al.* Nerve-spring technique could achieve a functional trifecta outcome of robotic intracorporeal studer's orthotopic neobladder in the male. *Bladder (San Franc).* 2022;9(1):e50. doi: 10.14440/bladder.2022.850
11. Cerantola Y, Valerio M, Persson B, *et al.* Guidelines for perioperative care after radical cystectomy for bladder cancer: Enhanced Recovery After Surgery (ERAS®) society recommendations. *Clin Nutr.* 2013;32(6):879-887. doi: 10.1016/j.clnu.2013.09.014
12. Williams SB, Cumberbatch MGK, Kamat AM, *et al.* Reporting radical cystectomy outcomes following implementation of enhanced recovery after surgery protocols: A systematic review and individual patient data meta-analysis. *Eur Urol.* 2020;78(5):719-730. doi: 10.1016/j.eururo.2020.06.039
13. Borgmann H, Cooperberg M, Murphy D, *et al.* Online professionalism-2018 update of european association of urology (@Uroweb) recommendations on the appropriate use of social media. *Eur Urol.* 2018;74(5):644-650. doi: 10.1016/j.eururo.2018.08.022
14. Powles T, Bellmunt J, Comperat E, *et al.* Bladder cancer: ESMO clinical practice guideline for diagnosis, treatment and follow-up. *Ann Oncol.* 2022;33(3):244-258. doi: 10.1016/j.annonc.2021.11.012
15. Comperat E, Amin MB, Cathomas R, *et al.* Current best practice for bladder cancer: A narrative review of diagnostics and treatments. *Lancet.* 2022;400(10364):1712-1721. doi: 10.1016/S0140-6736(22)01188-6
16. Check DK, Leo MC, Banegas MP, *et al.* Decision regret related to urinary diversion choice among patients treated with cystectomy. *J Urol.* 2020;203(1):159-163. doi: 10.1097/ju.0000000000000512
17. Alfred Witjes J, Max Bruins H, Carrión A, *et al.* European association of urology guidelines on muscle-invasive and metastatic bladder cancer: Summary of the 2023 guidelines. *Eur Urol.* 2024;85(1):17-31. doi: 10.1016/j.eururo.2023.08.016
18. Tyritzis SI, Hosseini A, Collins J, *et al.* Oncologic, functional, and complications outcomes of robot-assisted radical cystectomy with totally intracorporeal neobladder diversion. *Eur Urol.* 2013;64(5):734-741. doi: 10.1016/j.eururo.2013.05.050
19. Katayama S, Mori K, Pradere B, *et al.* Intracorporeal versus extracorporeal urinary diversion in robot-assisted radical cystectomy: A systematic review and meta-analysis. *Int J Clin Oncol.* 2021;26(9):1587-1599. doi: 10.1007/s10147-021-01972-2
20. Tanneru K, Jazayeri SB, Kumar J, *et al.* Intracorporeal versus extracorporeal urinary diversion following robot-assisted radical cystectomy: A meta-analysis, cumulative analysis, and systematic review. *J Robot Surg.* 2021;15(3):321-333. doi: 10.1007/s11701-020-01174-4
21. Mistretta FA, Musi G, Colla Ruvolo C, *et al.* Robot-assisted radical cystectomy for nonmetastatic urothelial carcinoma of urinary bladder: A comparison between intracorporeal versus extracorporeal orthotopic ileal neobladder. *J Endourol.* 2021;35(2):151-158.

- doi: 10.1089/end.2020.0622
22. You C, Du Y, Wang H, *et al.* Robot-assisted radical cystectomy with intracorporeal urinary diversion: A new standard of urinary diversion. *J Endourol.* 2021;35(4):473-482. doi: 10.1089/end.2020.0760
 23. Tyritzis SI, Hosseini A, Jonsson M, Adding C, Nilsson A, Wiklund NP. Robot-assisted intracorporeal formation of the ileal neobladder. *J Endourol.* 2012;26(12):1570-1575. doi: 10.1089/end.2012.0424
 24. Chopra S, de Castro Abreu AL, Berger AK, *et al.* Evolution of robot-assisted orthotopic ileal neobladder formation: A step-by-step update to the University of Southern California (USC) technique. *BJU Int.* 2017;119(1):185-191. doi: 10.1111/bju.13611
 25. Tan WS, Sridhar A, Goldstraw M, *et al.* Robot-assisted intracorporeal pyramid neobladder. *BJU Int.* 2015;116(5):771-779. doi: 10.1111/bju.13189
 26. Asimakopoulos AD, Campagna A, Gakis G, *et al.* Nerve sparing, robot-assisted radical cystectomy with intracorporeal bladder substitution in the male. *J Urol.* 2016;196(5):1549-1557. doi: 10.1016/j.juro.2016.04.114
 27. Simone G, Papalia R, Misuraca L, *et al.* Robotic intracorporeal padua ileal bladder: Surgical technique, perioperative, oncologic and functional outcomes. *Eur Urol.* 2018;73(6):934-940. doi: 10.1016/j.eururo.2016.10.018
 28. Balbay MD, Koseoglu E, Canda AE, *et al.* Endopelvic fascia sparing robotic radical cystectomy with intracorporeal studer pouch with Balbay's technique. *JSLS.* 2022;26(3):e2022.00031. doi: 10.4293/JSLS.2022.00031
 29. Piramide F, Turri F, Amparore D, *et al.* Atlas of intracorporeal orthotopic neobladder techniques after robot-assisted radical cystectomy and systematic review of clinical outcomes. *Eur Urol.* 2024;85(4):348-360. doi: 10.1016/j.eururo.2023.11.017
 30. Smith ZL, Christodouleas JP, Keefe SM, Malkowicz SB, Guzzo TJ. Bladder preservation in the treatment of muscle-invasive bladder cancer (MIBC): A review of the literature and a practical approach to therapy. *BJU Int.* 2013;112(1):13-25. doi: 10.1111/j.1464-410X.2012.11762.x
 31. Kim JK, Park SY, Ahn HJ, Kim CS, Cho KS. Bladder cancer: Analysis of multi-detector row helical CT enhancement pattern and accuracy in tumor detection and perivesical staging. *Radiology.* 2004;231(3):725-731. doi: 10.1148/radiol.2313021253
 32. Barentsz JO, Jager GJ, Witjes JA, Ruijs JH. Primary staging of urinary bladder carcinoma: The role of MRI and a comparison with CT. *Eur Radiol.* 1996;6(2):129-133. doi: 10.1007/BF00181125
 33. Ha HK, Koo PJ, Kim SJ. Diagnostic accuracy of F-18 FDG PET/CT for preoperative lymph node staging in newly diagnosed bladder cancer patients: A systematic review and meta-analysis. *Oncology.* 2018;95(1):31-38. doi: 10.1159/000488200
 34. Wilson TG, Guru K, Rosen RC, *et al.* Best practices in robot-assisted radical cystectomy and urinary reconstruction: Recommendations of the pasadena consensus panel. *Eur Urol.* 2015;67(3):363-375. doi: 10.1016/j.eururo.2014.12.009
 35. Cheng Q, Gao F, Chen WZ, *et al.* Analysis of CUSUM learning curve of robotic intracorporeal Studer's orthotopic neobladder. *J Minim Invasive Urol.* 2023;12(06):365-369. [In Chinese]. doi: 10.19558/j.cnki.10-1020/r.2023.06.002
 36. Tuderti G, Mastroianni R, Brasseti A, *et al.* Robot-assisted radical cystectomy with intracorporeal neobladder: Impact of learning curve and long-term assessment of functional outcomes. *Minerva Urol Nephrol.* 2021;73(6):754-762. doi: 10.23736/S2724-6051.20.03948-X
 37. Wei H, Wang M, Wasilijiang W, *et al.* Modified ileal conduit intracorporeally accomplished following laparoscopic radical cystectomy with enhanced recovery protocols: Experience with 48 cases. *Transl Androl Urol.* 2021;10(4):1596-1606. doi: 10.21037/tau-20-1515
 38. Furrer MA, Studer UE, Gross T, Burkhard FC, Thalmann GN, Nguyen DP. Nerve-sparing radical cystectomy has a beneficial impact on urinary continence after orthotopic bladder substitution, which becomes even more apparent over time. *BJU Int.* 2018;121(6):935-944. doi: 10.1111/bju.14123
 39. Hernandez V, Espinos EL, Dunn J, *et al.* Oncological and functional outcomes of sexual function-preserving cystectomy compared with standard radical cystectomy in men: A systematic review. *Urol Oncol.* 2017;35(9):539.e17-539.e29. doi: 10.1016/j.urolonc.2017.04.013
 40. Kretschmer A, Grimm T, Buchner A, *et al.* Prognostic features for objectively defined urinary continence after radical cystectomy and ileal orthotopic neobladder in a contemporary cohort. *J Urol.* 2017;197(1):210-215. doi: 10.1016/j.juro.2016.08.004
 41. Clifford TG, Shah SH, Bazargani ST, *et al.* Prospective evaluation of continence following radical cystectomy and orthotopic urinary diversion using a validated questionnaire. *J Urol.* 2016;196(6):1685-1691. doi: 10.1016/j.juro.2016.05.093
 42. Satkunasivam R, Santomauro M, Chopra S, *et al.* Robotic intracorporeal orthotopic neobladder: Urodynamic outcomes, urinary function, and health-related quality of life. *Eur Urol.* 2016;69(2):247-253. doi: 10.1016/j.eururo.2015.06.041
 43. Benamran D, Phe V, Drouin SJ, *et al.* Functional outcomes obtained with intracorporeal neobladder after robotic radical cystectomy for cancer: A narrative review. *J Robot Surg.* 2020;14(6):813-820. doi: 10.1007/s11701-020-01070-x



This article is an open access article distributed under the terms and conditions of the Creative Commons Attribution 4.0 International License (<https://creativecommons.org/licenses/by/4.0/>)