

# Advanced UltraTech approach for distinguishing granulomatous from non-granulomatous corneal endothelial exudates in autoimmune rheumatic anterior uveitis

Roberta Foti<sup>1</sup> , Marco Zeppieri<sup>2\*</sup> , Rosario Foti<sup>1</sup> , Ylenia Dal Bosco<sup>1</sup> , Davide Scollo<sup>3</sup> , Elisa Visalli<sup>1</sup> , Salvatore Ficili<sup>3</sup> ,  
Giorgio Amato<sup>1</sup> , Valentina Cifalinò<sup>3</sup> , Riccardo Foti<sup>4</sup> , Alessandro Avitabile<sup>5</sup> , Ludovica Cannizzaro<sup>5</sup> , Caterina Gagliano<sup>6,7</sup> 

<sup>1</sup>Division of Rheumatology, Policlinico-San Marco Academic Hospital (AOU), 95123 Catania, Italy

<sup>2</sup>Department of Ophthalmology, University Hospital of Udine, 33100 Udine, Italy

<sup>3</sup>Eye Clinic, Catania University, San Marco Hospital, 95121 Catania, Italy

<sup>4</sup>Department of Surgical Sciences, Plastic and Reconstructive Surgery, University of Rome Tor Vergata, 00133 Rome, Italy

<sup>5</sup>Faculty of Medicine, University of Catania, 95123 Catania, Italy

<sup>6</sup>Department of Medicine and Surgery, University of Enna Kore, 94100 Enna, Italy

<sup>7</sup>Mediterranean Foundation “G.B. Morgagni”, 95125 Catania, Italy

## Abstract

**Background:** Anterior uveitis is a common manifestation in individuals with rheumatic conditions such as spondylarthritis, Behçet’s syndrome, juvenile idiopathic arthritis, and sarcoidosis. Clinical differentiation between granulomatous and non-granulomatous corneal endothelial exudates is crucial to subsequent diagnosis and treatment. Anterior segment optical coherence tomography (AS-OCT) can ensure an accurate differential diagnosis and appropriate follow-up after local and systemic therapy. **Objective:** This study aimed to distinguish between granulomatous and non-granulomatous endothelial exudates in patients with anterior uveitis using AS-OCT. **Methods:** This longitudinal observational study involved 30 patients diagnosed with or suspected of having rheumatic autoimmune disease presenting with anterior uveitis. The study was conducted at the combined Rheumatology and Ophthalmology Clinic, San Marco Hospital, Catania, Italy. All patients underwent slit-lamp examination, which revealed or suspected corneal endothelial exudates. A comprehensive rheumatological and ophthalmological evaluation was also performed. Subsequently, the patients were subjected to AS-OCT using the Optovue Solix device. **Results:** Granulomatous corneal exudates were identified in 30% of the subjects, with counts ranging from 5 to 20 and sizes varying between 50 and 150  $\mu\text{m}$ . Detailed 3D scans further exhibited the morphology of these exudates. A follow-up of patients after steroid therapy (both topical and systemic) and immunosuppressive treatment demonstrated a progressive reduction in the exudates, ultimately leading to their complete resolution. **Conclusion:** Use of ophthalmological equipment that allows for simple, rapid, and non-invasive investigations in combination with a multidisciplinary approach, enables appropriate diagnosis and monitoring of therapeutic efficacy in patients with inflammatory ocular conditions presenting with corneal endothelial exudates.

**Keywords:** Corneal endothelial exudates, Anterior uveitis, Autoimmune diseases, Spondylarthritis, Behçet’s syndrome, Anterior segment optical coherence tomography

## 1. INTRODUCTION

Anterior uveitis represents the most frequently encountered subtype of uveitis, characterized by inflammation localized to the front segment of the eye. This condition accounts for the majority of uveitis cases and typically presents with redness, pain, light sensitivity, and blurred vision. The anterior segment includes such structures as the iris and the anterior chamber, which are often directly affected by the inflammation. This type of uveitis can result from a variety of causes, including idiopathic factors, infections (both viral and bacterial), autoimmune disorders, and trauma. Given its prevalence, anterior uveitis poses a significant ophthalmological concern, requiring prompt diagnosis and appropriate management

\*Corresponding author:

Marco Zeppieri (mark.zeppieri@asufc.sanita.fvg.it)

This is an open-access article under the terms of the Creative Commons Attribution License, which permits use, distribution, and reproduction in any medium, provided the original work is properly cited.

© 2024 Journal of Biological Methods published by POL Scientific

Received: 31 July 2024; Revision received: 19 September 2024;

Accepted: 23 September 2024; Published: 7 November 2024

**How to cite this article:** Foti R, Zeppieri M, Foti R, *et al.* Advanced UltraTech approach for distinguishing granulomatous from non-granulomatous corneal endothelial exudates in autoimmune rheumatic anterior uveitis. *J Biol Methods.* 2024;11(4):e99010034. DOI: 10.14440/jbm.2024.0049

to prevent complications and preserve vision. Clinical presentation of anterior uveitis can vary widely, ranging from mild to severe forms. Indeed, in more severe cases, the inflammation can lead to intense pain, pronounced redness, and significant visual disturbances, sometimes accompanied by headaches. These symptoms necessitate a thorough clinical evaluation to determine the exact etiology and to rule out other potential ocular or systemic conditions. Anterior uveitis can be classified as acute or chronic. Acute anterior uveitis typically has a sudden onset and a short duration, often resolving within weeks on appropriate treatment. Chronic anterior uveitis, on the other hand, persists for longer periods and can be recurrent, necessitating prolonged management and monitoring [1]. The underlying causes of anterior uveitis are diverse. Idiopathic cases, where no specific cause is identified, are common. However, autoimmune conditions, such as ankylosing spondylitis, juvenile idiopathic arthritis (JIA), and sarcoidosis, are well-known contributors. Infections, like infections with herpes simplex virus (HSV), varicella-zoster virus (VZV), and syphilis, can also trigger anterior uveitis. Trauma to the eye, including surgical procedures, can also precipitate the condition. Management of anterior uveitis involves addressing the underlying cause when identifiable and suppressing inflammation to prevent complications such as glaucoma, cataracts, or permanent vision loss. Treatment often includes corticosteroid eye drops to reduce inflammation, dilating drops to prevent synechiae formation (adhesions between the iris and the lens), and immunosuppressive drugs in more severe or chronic cases. Regular follow-up with an ophthalmologist is crucial to monitoring of the condition and treatment adjustment when necessary [2]. In Western countries, anterior uveitis is notably prevalent, accounting for approximately 90% of all uveitis cases in primary care settings. In more specialized medical environments, such as tertiary referral centers, the prevalence of anterior uveitis is somewhat lower but still substantial, constituting about 50%–60% of all uveitis cases [3]. Idiopathic forms, where the cause is not identified, comprise most cases of anterior uveitis. Infectious causes are also significant, particularly viral infections such as HSV, VZV, and cytomegalovirus (CMV). Autoimmune disorders frequently lead to anterior uveitis, with JIA, ankylosing spondylitis, and sarcoidosis being the most common causes. Eye trauma is another common cause, and systemic infectious diseases like tuberculosis and syphilis are also known to trigger the condition. Understanding these varied causes is essential for the proper management of the condition [4].

Anterior uveitis often develops in individuals with various rheumatic and systemic conditions. For instance, spondylarthritis associated with HLA-B27 frequently presents with recurrent eye inflammation, notably uveitis, which can be a significant clinical manifestation among the articular

involvement. HLA-B27, a genetic marker, is strongly linked to the pathogenesis of this autoimmune condition, leading to chronic or episodic inflammation that affects the eyes and can result in complications if not adequately managed. Several studies have reported that acute anterior uveitis is the most frequent ocular disorder associated with HLA-B27 [1-5], with patients often suffering from recurrent episodes that require careful management to prevent long-term damage.

Behçet's syndrome, a chronic condition causing widespread blood vessel inflammation, commonly leads to anterior uveitis. It is characterized by systemic inflammation of the blood vessels, affecting multiple organ systems. One of the hallmark features of Behçet's syndrome is its recurrent, relapsing course of symptoms, such as oral and genital ulcers, which can significantly impact a patient's quality of life. The pathogenesis is complex and not fully understood, but it is believed to involve both genetic and environmental factors. The HLA-B51 gene has been found to be strongly associated with an increased risk for developing the disease, particularly in certain ethnic groups. Treatment of Behçet's syndrome focuses on controlling the inflammation and preventing flare-ups. This often involves using immunosuppressive drugs such as corticosteroids and biological agents like tumor necrosis factor (TNF) inhibitors. Due to its systemic nature, it can also present with various manifestations, including skin lesions, gastrointestinal issues, and neurological manifestations [6]. JIA, a condition that affects children and leads to persistent joint inflammation and stiffness, often includes anterior uveitis as a severe complication. Anterior uveitis associated with JIA can be particularly insidious because it frequently presents without the classic symptoms of eye inflammation, such as red eye, pain, photophobia, and blurred vision. JIA is the most common chronic rheumatic disease in children and can be classified into several subtypes based on the number of joints affected and other clinical features. Moreover, regular ophthalmological screening is crucial to the early detection of uveitis in children with JIA, even without symptoms. Treatment of JIA-associated anterior uveitis often involves combining topical corticosteroids to reduce eye inflammation and immunosuppressive medications to control the underlying autoimmune activity. Biological agents, such as TNF inhibitors, have also demonstrated efficacy in the treatment of both JIA and associated uveitis, improving long-term outcomes for affected children [7]. Sarcoidosis, characterized by tiny collections of inflammatory cells known as granulomas, can affect multiple organs in the body, including the eyes. Anterior uveitis is a common ocular manifestation of sarcoidosis. Lacrimal gland involvement may lead to symptoms like proptosis (bulging of the eye) and diplopia due to the mass effect. Managing sarcoidosis-related uveitis often involves using corticosteroids [8] to mitigate inflammation and immunosuppressive agents to

control the underlying immune response. Ocular symptoms can sometimes appear before systemic symptoms [9], serving as an early warning sign of a broader condition. Early recognition enables comprehensive treatment, addressing both the eye inflammation and the primary disease, which can prevent complications and improve patient outcomes. This underscores the need for interdisciplinary collaboration among ophthalmologists, rheumatologists, infectious disease specialists, and other healthcare professionals.

The aforementioned classification of anterior uveitis is just one method of categorization. Uveitis can also be classified etiologically into infectious or non-infectious uveitis, depending on the underlying cause, and histopathologically into granulomatous or non-granulomatous uveitis according to the body's immunological response to the cause of the uveitis [10]. Granulomatous exudates differ from the non-granulomatous ones by a more substantial accumulation of epithelioid and giant cells. Clinically, non-granulomatous exudates tend to present with a dust-like and homogeneous distribution. In contrast, granulomatous exudates are generally larger, aggregated, and tend to settle in the lower part of the cornea [11]. Moreover, granulomatous exudates are characterized by larger, greasy-appearing mutton-fat deposits. In contrast, non-granulomatous exudates tend to be more commonly associated with infectious causes, such as viral or bacterial infections [12-14]. They are usually smaller and less prominent than their granulomatous counterparts. The pathophysiology of granulomatous uveitis varies with the underlying cause but generally follows a similar mechanism [15]. Antigen-presenting cells (APCs) in the tissue, such as dendritic cells and monocytes in the bloodstream, detect an antigen. These cells present the antigen to T helper cells, triggering the recruitment and activation of additional monocytes and lymphocytes to the affected.

It is important to understand the mechanisms involved in the induction of cellular immunity and effector CD4 T cells. The initiation of cellular immunity is an intricate process that encompasses several stages, commencing with the identification of antigens and culminating with the stimulation and specialization of CD4 T cells into diverse effector subsets. Dendritic cells and other APCs process and present peptide fragments on major histocompatibility complex (MHC) Class II molecules when they come into contact with an antigen.

Nevertheless, the activation of CD4 T cells does not rely on TCR interaction alone. Co-stimulatory signals, which are crucial for complete activation, are facilitated by molecules like CD80 and CD86 on the APCs that bind to CD28 on the T cell. Without these signals, T cells may become anergic or experience apoptosis, emphasizing the significance of co-stimulation in immune activation

Cytokine settings additionally impact the differentiation of activated CD4 T cells into specific effector subsets, each fulfilling diverse functions in the immune response. For example, interleukin-12 (IL-12) promotes the development of Th1 cells, which play a vital role in initiating immune responses against intracellular infections by releasing interferon-gamma. Th2 cells, stimulated by IL-4, are important for the production of antibodies and play a crucial role in defending against infections that are located outside of cells. Th17 cells, which are activated by IL-6 and transforming growth factor-beta (TGF- $\beta$ ), play a crucial role in inflammation and the immune response against extracellular bacteria and fungi. Tregs, induced by TGF- $\beta$  in the absence of pro-inflammatory cytokines, play a crucial role in preserving immunological balance and preventing autoimmunity.

Lymphocytes, specifically CD4 T cells, and monocytes are attracted to areas of inflammation or infection through a mix of signals. Chemokines and cytokines are crucial in this process. In the setting of autoimmune illnesses or inflammatory disorders, such as anterior uveitis, these molecules are generated by immune cells that are already present, as well as by endothelial cells and even the afflicted tissue itself, in response to the existence of autoantigens or other inflammatory triggers.

On being recruited to the site of inflammation, these cells undergo additional activation through interactions with antigens presented by APCs such as dendritic cells and macrophages. These APCs display the antigens using MHC Class II molecules to CD4 T cells, which triggers their activation. Concurrently, monocytes can transform into macrophages or dendritic cells due to specific signals from the surrounding environment, thereby enhancing the inflammatory reaction.

Effector CD4 T lymphocytes are primarily generated in secondary lymphoid organs, such as lymph nodes, the spleen, and mucosa-associated lymphoid tissues. These organs serve as the principal sites where naïve T lymphocytes encounter their specific antigens. Dendritic cells, on capturing antigens in peripheral tissues, migrate to the lymph nodes and present these antigens to naïve CD4 T cells. The lymph node provides a highly organized environment where T lymphocytes receive the necessary signals for activation [16], proliferation, and differentiation into effector cells. Research has demonstrated that the transition of CD4 T cells from a naïve to an effector state is dependent on late-stage interactions with the antigen, occurring within secondary lymphoid organs, where the immunological milieu supports their differentiation. This process is critical for mounting an effective adaptive immune response [17] and for the establishment of immunological memory.

Granulomatous inflammation of the uveal tract can result from various infectious and non-infectious conditions.



Infectious causes include tuberculosis, syphilis, herpes viruses such as HSV [18] and VZV, CMV, Lyme disease, toxoplasmosis, and toxocariasis. Other infections, such as trematodes, *Propionibacterium acnes*, and post-streptococcal infections, can also lead to granulomatous uveitis. In addition, fungal infections such as candidiasis, histoplasmosis, and cryptococcosis, sometimes associated with SARS-COV-2, are implicated. Moreover, other etiological factors include infiltrative and ischemic conditions.

Non-infectious causes encompass a range of systemic and autoimmune conditions. Sarcoidosis, multiple sclerosis, Vogt-Koyanagi-Harada disease, psoriatic arthritis, and sympathetic ophthalmia are notable examples. Lymphoma, Blau syndrome, and histiocytosis also fall under this category. Moreover, other non-infectious triggers include granuloma annulare, lens-induced uveitis, and drug-induced reactions, particularly from medications such as brimonidine and pembrolizumab. Idiopathic cases, like multifocal choroiditis, and conditions, like a common variable immune deficiency, can also cause granulomatous inflammation. In addition, high-density silicone oil tamponade [19] and intraocular foreign bodies, including caterpillar hair and tattoo-associated granulomatous uveitis, are recognized non-infectious causes. In contrast, acute, unilateral, and non-granulomatous uveitis is the most frequently encountered form of uveitis globally. Non-granulomatous uveitis makes up the majority of uveitis cases, ranging from 51% to 89% [20].

It is evident that, particularly in cases where ocular manifestations precede systemic manifestations, the rheumatologist must distinguish between various forms of uveitis. This distinction is significantly facilitated by close collaboration with ophthalmologists. Prompt differentiation between granulomatous and non-granulomatous forms of anterior uveitis is essential, even though it is not an easy task. Such differentiation expedites the diagnostic process and allows for the timely initiation of appropriate therapeutic interventions for the patient. It has been reported that early and accurate identification of uveitis types [21] can significantly influence treatment outcomes. Recognizing that ocular manifestations can precede systemic ones, rheumatologists need to differentiate between forms of uveitis. This task, greatly aided by close collaboration with ophthalmologists, involves distinguishing granulomatous from non-granulomatous anterior uveitis. Accurate differentiation, although challenging, expedites diagnosis and facilitates timely therapeutic interventions [L1] [RF2]. Current literature has reported the critical role of this interdisciplinary approach, demonstrating that early identification of uveitis types [22] significantly improves treatment outcomes.

Anterior segment optical coherence tomography (AS-OCT) is a non-invasive imaging technique that captures

high-resolution cross-sectional images of the eye's anterior segment. It provides detailed views of the corneal layers, anterior chamber, and other structures, making it a valuable tool for diagnosing and monitoring eye diseases. AS-OCT uses low-coherence interferometry to achieve micrometer-resolution imaging. It employs a broadband light source, usually in the near-infrared spectrum, which penetrates eye tissues and reflects off different structures. The interferometer measures the time delay and intensity of the reflected light, creating detailed cross-sectional images similar to ultrasound but with much higher resolution [23]. Recent research has significantly expanded the understanding of the role of AS-OCT in ophthalmology [24,25]. For instance, a 2023 study by Smith *et al.* demonstrated that AS-OCT can detect early signs of corneal graft rejection by visualizing subclinical changes in graft thickness and endothelial cell morphology, thus allowing for timely intervention [26]. In pediatric ophthalmology, a 2022 review by Jones *et al.* emphasized the utility of AS-OCT in diagnosing congenital anomalies such as anterior segment dysgenesis and pediatric cataracts without the need for sedation [27]. Recent studies have reported that AS-OCT could effectively monitor changes in the ocular surface in diseases such as dry eye syndrome and pterygium [27,28]. This technology provides objective measurements of tear film thickness [28] and conjunctival tissue, aiding in accurate diagnosis and management. Innovations in the management of keratoconus have also been highlighted. A 2022 study by Seiler *et al.* explored the repeatability of and compared corneal tomography in mild to severe keratoconus between the AS-OCT MS-39 and Pentacam HR, highlighting the utility of AS-OCT in the accurate detection and management of keratoconus. Their findings indicated that AS-OCT can identify subtle stromal changes and epithelial thinning before clinical signs become apparent, potentially leading to earlier and more effective treatment [29]. The aim of this study was to use AS-OCT technology to accurately identify and differentiate between granulomatous and non-granulomatous endothelial exudates in a cohort of patients with anterior uveitis.

## 2. METHODS

This longitudinal observational study aimed to improve the diagnostic and therapeutic approaches for anterior uveitis in patients with rheumatic autoimmune diseases. Conducted at the Rheumatology and Ophthalmology Clinic, San Marco Hospital, Catania, Italy, the study followed 30 patients over time. These patients were either diagnosed with or suspected of having rheumatic autoimmune diseases and presented with anterior uveitis. Patients with strongly suspected ocular infections were excluded to ensure a more focused study on autoimmune etiologies.

Participants were selected as they presented to the clinic, allowing for a real-world approach to patient enrolment. Each patient provided informed consent before participating in the study. The ethical standards were followed and an effort was made to ensure that all participants understood the study's purpose and procedures.

The rheumatologic evaluation for each patient began with taking of a comprehensive medical history. This history-taking included inquiries about previous or current autoimmune conditions, medication usage, and overall health status. Blood tests were conducted to assess inflammatory markers such as C-reactive protein and erythrocyte sedimentation rate, which are crucial for understanding the systemic inflammatory status of the patients. Additional laboratory tests that were requested included antinuclear antibodies, extractable nuclear antigens, and also HLA-B27 testing. These markers helped correlate systemic inflammation with ocular symptoms, providing a broader picture of the patient's health.

A thorough ophthalmological assessment was conducted, including several key examinations. Each patient underwent a slit-lamp examination, which is essential for detailed observation of the anterior segment of the eye. This examination allowed for the identification or evaluation of corneal endothelial exudates indicative of anterior uveitis. Fundus examinations were performed to evaluate the status of the retina and optic nerve, ensuring no posterior segment involvement complicated the clinical picture. Visual acuity tests were also conducted to measure the clarity of each patient's vision, providing an objective measure of visual function and assessing the impact of uveitis on the patient's vision.

Following these traditional evaluations, the study utilized advanced imaging techniques. Each patient underwent AS-OCT on the Optovue Solix device. This non-invasive imaging technology is renowned for its high-resolution imaging and rapid scanning capabilities, making it particularly useful for detailed assessment of the anterior segment. The AS-OCT provided clear, cross-sectional images of the front part of the eye, including the cornea, iris, and lens. These images were crucial in distinguishing between granulomatous and non-granulomatous endothelial exudates, essential for understanding the underlying causes of anterior uveitis and tailoring appropriate treatment strategies.

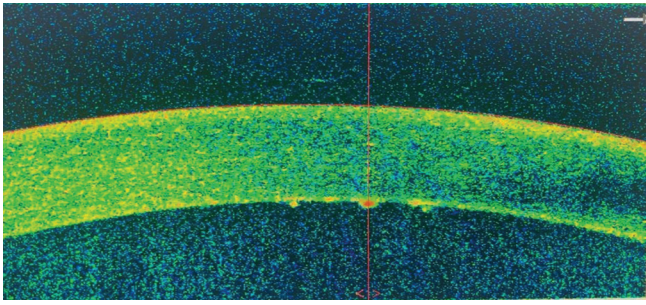
The images and data obtained from the AS-OCT examinations were carefully analyzed. Patterns and features indicative of granulomatous versus non-granulomatous inflammation were identified and correlated with the findings from the slit-lamp examinations, fundus examinations, and visual acuity tests. This integrative approach yielded a comprehensive diagnostic profile for each patient, enhancing the understanding of anterior uveitis in the context of rheumatic autoimmune diseases.

By combining detailed patient histories, thorough rheumatological and ophthalmological evaluations, and advanced imaging technology, this study aimed to enhance the diagnostic and therapeutic paradigms for anterior uveitis.

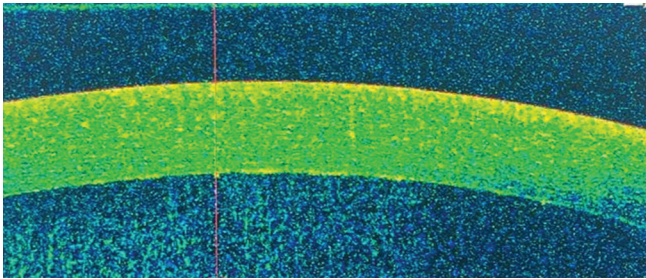
### 3. RESULTS

Granulomatous corneal exudates were identified in 30% of the examined subjects, with counts ranging from 5 to 20 and sizes varying between 50 and 150  $\mu\text{m}$ . Detailed 3D scans provided insights into the morphology of these exudates. A follow-up of patients after steroid therapy (both topical and systemic) and immunosuppressive treatment demonstrated a progressive reduction in the exudates, ultimately leading to their complete resolution. We used the following features to distinguish granulomatous from non-granulomatous corneal endothelial exudates using AS-OCT:

- (i) Granulomatous corneal endothelial exudates:
  - Hyperreflective nodules: Granulomatous exudates often appear as discrete, hyperreflective nodules on the endothelium.
  - Location and pattern: These nodules can be scattered or clustered, often seen in conditions like sarcoidosis, tuberculosis, or fungal infections.
  - Size and shape: The nodules are typically well-defined and can vary in size.
  - Associated findings: There may be other signs of granulomatous inflammation, such as keratic precipitates (KP), anterior chamber reaction, and possible iris nodules.
- (ii) Non-granulomatous corneal endothelial exudates:
  - Diffuse hyperreflective layer: Non-granulomatous exudates tend to present as a more diffuse, hyperreflective layer along the endothelium.
  - Location and pattern: These exudates often have a smoother, less nodular appearance, common in conditions like herpetic keratouveitis, viral keratitis, and bacterial infections.
  - Size and shape: The exudates are usually uniform and lack the discrete, nodular appearance of granulomatous types.
  - Associated findings: May present with diffuse corneal edema, stromal infiltrates, and a more generalized anterior chamber reaction.
- (iii) AS-OCT imaging characteristics
  - Granulomatous exudates are highly reflective, well-demarcated nodules, posterior shadowing along the endothelium (Figure 1).
  - Non-granulomatous exudates appear as a homogeneous, reflective band without distinct nodules and have less pronounced shadowing compared to granulomatous exudates (Figure 2).



**Figure 1.** Anterior segment optical coherence tomographic imaging of granulomatous exudates.



**Figure 2.** Anterior segment optical coherence tomographic imaging of non-granulomatous exudates.

#### (iv) Clinical correlation

- History and symptoms: Patient history (*e.g.*, exposure to tuberculosis, history of autoimmune diseases) and symptoms (pain, redness, and vision changes) can provide context.
- Other diagnostic tools: Slit-lamp examination, confocal microscopy, and possible biopsy can be used for definitive diagnosis.
- Response to treatment: Granulomatous conditions may require more prolonged and specific anti-inflammatory or antimicrobial treatments.

Table 1 provides a detailed summary of the distinguishing features between granulomatous and non-granulomatous exudates, which are essential for accurate diagnosis and treatment. Granulomatous exudates are characterized by their appearance on AS-OCT as discrete, hyperreflective nodules. These nodules can appear scattered or clustered throughout the affected area. Their sizes are variable but well-defined, which aids in their identification. Clinically, granulomatous exudates are often associated with KP, an anterior chamber reaction, and the presence of iris nodules. In contrast, non-granulomatous exudates display a diffuse, hyperreflective layer on AS-OCT, lacking the discrete nodules observed in granulomatous exudates. The pattern of non-granulomatous exudates is smooth and less nodular, presenting a more uniform appearance. These exudates tend to be less defined in shape and size, contributing to their diffuse nature. Associated clinical findings include diffuse corneal edema and stromal infiltrates, which can indicate the severity of the underlying condition. Understanding these

differences is crucial for clinicians as it helps them accurately differentiate between granulomatous and non-granulomatous conditions, leading to more targeted and effective treatment. The precise identification of these features on AS-OCT and associated clinical findings provides a comprehensive approach to managing ocular diseases with varying exudative presentations.

Following the initial identification and characterization of granulomatous and non-granulomatous corneal endothelial exudates, a comprehensive follow-up was conducted on the affected patients. This follow-up involved administering steroid therapy, both topical and systemic, tailored to the severity and nature of the condition. In addition, various immunosuppressive treatments were employed and customized according to the underlying diagnosis of rheumatic condition. The follow-up protocol included AS-OCT examinations at regular intervals. These repeated scans were crucial for several reasons:

- (i) Monitoring treatment efficacy: By comparing the initial AS-OCT scans with those taken during follow-up visits, we were able to observe the progressive reduction in the exudates. This comparison provided clear evidence of the effectiveness of the prescribed therapies.
- (ii) Detailed documentation: The ability to document changes in the exudates over time allowed for a more accurate assessment of the healing process. It also helped in identifying any residual or recurring inflammation that might require further intervention.
- (iii) Clinical decision-making: The repeated imaging data supported clinicians in making informed decisions about continuing, adjusting, or changing the treatment regimens. For instance, if a patient showed significant improvement, the dosage of steroids or immunosuppressive drugs could be tapered off gradually.
- (iv) Patient reassurance: Demonstrating visual improvements in their condition through AS-OCT imaging provided patients with reassurance and a better understanding of their progress, thereby improving adherence to treatment plans.

Overall, the follow-up strategy was instrumental in ensuring that the therapeutic interventions were effective in reducing and ultimately resolving the granulomatous and non-granulomatous corneal endothelial exudates. The detailed documentation and comparison of AS-OCT scans before and after treatment validated the clinical approach and highlighted the importance of ongoing monitoring in managing complex ocular conditions.

## 4. DISCUSSION

The collaboration between ophthalmologists and rheumatologists in this study has proven essential in effectively



**Table 1.** Distinguishing features of the two exudates

Feature	Granulomatous exudates	Non-granulomatous exudates
Appearance on AS-OCT	Discrete, hyperreflective nodules	Diffuse, hyperreflective layer
Pattern	Scattered or clustered nodules	Smooth, less nodular
Size and shape	Well-defined, varying sizes	Uniform, less defined
Associated findings	Keratic precipitates, anterior chamber reaction, iris nodules	Diffuse corneal edema, stromal infiltrates

AS-OCT: Anterior segment optical coherence tomography.

diagnosing and managing anterior uveitis in patients with rheumatic autoimmune diseases. Using AS-OCT, particularly with the Optovue Solix device, has significantly improved the ability to distinguish between granulomatous and non-granulomatous endothelial exudates. This differentiation is crucial as it directly influences treatment decisions and patient outcomes.

AS-OCT has demonstrated clear advantages over less innovative methods [30]. The extreme precision of the images obtained from tomographic data allows for immediate detection and subsequent follow-up of corneal exudates through a non-invasive technique [31]. This capability is precious in clinical settings where prompt diagnosis can lead to quicker therapeutic interventions, potentially preventing complications and preserving vision.

The detailed imaging provided by AS-OCT helps visualize the corneal layers and other anterior segment structures, which is essential for diagnosing eye diseases. Compared to traditional methods, AS-OCT offers higher resolution and more precise imaging, which facilitates better monitoring and management of conditions such as anterior uveitis [32].

In our study, we observed that granulomatous corneal exudates were present in 30% of the patients. These exudates varied in number and size but were effectively identified and monitored using AS-OCT. The visualization of these exudates in such detail enabled us to tailor steroids and immunosuppressive therapies more accurately. The follow-up scans revealed a progressive reduction in the exudates, confirming the effectiveness of the treatments.

The integration of comprehensive rheumatological and ophthalmological evaluations was also vital. Detailed medical histories and blood tests during the rheumatological assessments provided a thorough understanding of the patient's systemic conditions, which was crucial for interpreting the ocular findings. The ophthalmological assessments, including fundus examinations and visual acuity tests, complemented the AS-OCT findings and ensured a holistic approach to patient care.

This study highlighted the importance of interdisciplinary collaboration in managing complex conditions like anterior uveitis. The use of AS-OCT, with its high-resolution imaging capabilities, not only speeds up the diagnostic process but also enhances the precision of diagnoses. This technology

is straightforward and can be routinely employed in clinical practice to improve the accuracy of uveitis diagnosis and management.

Adopting AS-OCT as a standard diagnostic tool allows healthcare providers to offer better-targeted treatments, ultimately improving patient outcomes. The findings from this study support the broader use of AS-OCT in clinical settings, emphasizing its role in advancing the diagnosis and treatment of anterior uveitis associated with rheumatic autoimmune diseases.

In addition to the above-mentioned points, our study underscored the long-term benefits of using AS-OCT in routine clinical practice. The precision and reliability of AS-OCT imaging not only facilitate early detection but also allow for meticulous monitoring of disease progression and treatment response. This is particularly crucial with chronic conditions where ongoing assessment is necessary to adjust therapeutic strategies effectively. Furthermore, the non-invasive nature of AS-OCT ensures patient comfort and compliance, rendering it a preferred choice for both patients and clinicians. The ability to detect minute changes in the corneal structure with AS-OCT translates into more proactive and personalized patient care, ultimately leading to better management of anterior uveitis and associated rheumatic conditions. The positive outcomes observed in our study highlight the transformative potential of integrating advanced imaging technologies, like AS-OCT, into standard care protocols for improved patient outcomes.

Significant advancements have been achieved in comprehending the development and treatment of anterior uveitis, specifically in those with underlying rheumatic autoimmune conditions. Nevertheless, even with these advancements, difficulties remain in accurate differentiation between granulomatous and non-granulomatous corneal endothelial exudates. This distinction is crucial to customization of effective treatment approaches. Although AS-OCT has been used in numerous ocular disorders, its specific use in distinguishing between these two forms of exudates in the setting of autoimmune-related uveitis has not been thoroughly investigated.

This study reported certain aspects that are not widely known. This study utilized AS-OCT technology to distinguish between granulomatous and non-granulomatous corneal

endothelial exudates in individuals with autoimmune-related anterior uveitis. AS-OCT's ability to provide high-resolution images allows for a more comprehensive examination of the corneal endothelium, perhaps enhancing the accuracy of diagnoses compared to conventional techniques [33].

This work provided new insights into the impact of AS-OCT on treatment options for anterior uveitis by developing precise imaging criteria for two types of exudates. This can lead to more individualized and effective management of the condition.

To summarize, although the inflammation mechanisms and traditional diagnostic methods for uveitis are well-documented, the use of AS-OCT to differentiate corneal endothelial exudates is a new and valuable addition. This study not only expands existing knowledge base but also provides a fresh viewpoint on enhancing diagnostic accuracy and treatment results in this specific group of patients. To maintain a more targeted investigation of autoimmune causes, individuals with highly suspected ocular infections were deliberately excluded. The purpose of this exclusion criterion was to avoid any elements that could generate confusion and emerge from infectious causes of anterior uveitis. These infectious causes may involve different inflammation pathways and require specific treatment techniques. We recognize that the decision to exclude patients with suspected ocular infections may introduce selection bias, as the study only included individuals with non-infectious anterior uveitis related to rheumatic autoimmune disorders. Nevertheless, this decision was made to preserve the internal validity of the study by focusing on a uniform group of patients, thereby yielding more precise findings concerning the unique influence of autoimmune-related pathways on anterior uveitis. To minimize the influence of any selection bias, we made a deliberate effort to choose patients in a forward-looking manner as they arrived at our clinic without any prior information about their comprehensive medical background, except for the exclusion of infectious reasons. In addition, we included a wide spectrum of rheumatic autoimmune disorders in the study, which accurately represent the several causes of anterior uveitis that might arise from autoimmune factors.

Due to the observational nature of our study and the relatively small sample size of 30 patients, we focused on descriptive and qualitative analyses to offer an initial comprehension of the findings. This decision was made considering the study's objective to investigate and record preliminary observations rather than to carry out a detailed statistical analysis. Moreover, the investigation was undertaken with limited resources, which hindered our capacity to carry out more intricate statistical analyses. The main emphasis was on combining sophisticated imaging methods and clinical evaluations to tackle the study inquiry.

We focused on qualitative insights and descriptive statistics, especially using sophisticated AS-OCT imaging. Our objective was to provide the groundwork for future studies with comprehensive statistical analyses by enabling the application of more rigorous statistical analysis.

An inherent limitation of the study is its comparatively diminutive sample size, encompassing just 30 cases. The restricted sample size may limit the extrapolation of the results to a wider population, especially given the diversity of autoimmune disorders and their effects on the eyes. Furthermore, the investigation was conducted at a solitary facility, which may lead to potential biases associated with regional practice trends and patient demographics. By excluding individuals with suspected ocular infections, the study was able to focus specifically on autoimmune causes of anterior uveitis. However, this approach may have impaired the study's ability to provide a thorough understanding of the various causes of anterior uveitis. Another constraint is the study's observational design, which may not consider all possible confounding variables, such as differences in treatment compliance and the existence of comorbidities that could impact the results.

Moreover, the study excluded patients who were highly suspected of having eye infections to investigate autoimmune causes precisely. This exclusion may have affected the proportion of cases exhibiting granulomatous inflammation, as certain infections can manifest this kind of inflammation. Although AS-OCT offers high-resolution imaging and improves diagnostic accuracy, the identification result of granulomatous exudates might still vary, depending on the imaging method, interpretation, and clinical manifestation of the disease.

The recorded incidence of 30% must be understood in relation to the specific design and patient demographic of our investigation. This discovery emphasizes the necessity for additional investigation to examine the differences in the occurrence of granulomatous exudates among various groups and environments. Furthermore, it emphasizes the significance of ongoing progress in diagnostic methods to more effectively identify and distinguish between lesions of granulomatous and non-granulomatous nature.

## 5. CONCLUSION

The use of AS-OCT technology and the close collaboration between ophthalmologists and rheumatologists offer a straightforward, quick, and non-invasive way to diagnose and monitor anterior uveitis. This multidisciplinary approach ensures that patients with inflammatory eye conditions presenting with corneal endothelial exudates receive accurate diagnoses and effective treatment. Using advanced imaging techniques, healthcare providers can improve the precision of



their diagnoses and better track the effectiveness of therapeutic interventions, ultimately enhancing patient care. Applying these criteria with AS-OCT, clinicians can better differentiate between granulomatous and non-granulomatous corneal endothelial exudates, leading to more accurate diagnoses and appropriate management plans.

## ACKNOWLEDGMENTS

None.

## FUNDING

None.

## CONFLICT OF INTEREST

The authors declare no conflicts of interest.

## AUTHOR CONTRIBUTIONS

*Conceptualization:* Roberta Foti, Marco Zeppieri, Rosario Foti, Riccardo Foti, Alessandro Avitabile, Ludovica Cannizzaro, Caterina Gagliano

*Data curation:* All authors

*Formal analysis:* Roberta Foti, Rosario Foti, Giorgio Amato, Valentina Cifalinò, Riccardo Foti, Alessandro Avitabile, Ludovica Cannizzaro, Caterina Gagliano

*Investigation:* All authors

*Methodology:* All authors

*Project administration:* Roberta Foti, Marco Zeppieri, Rosario Foti, Riccardo Foti, Alessandro Avitabile, Ludovica Cannizzaro, Caterina Gagliano

*Resources:* Roberta Foti, Marco Zeppieri, Rosario Foti, Riccardo Foti, Alessandro Avitabile, Ludovica Cannizzaro, Caterina Gagliano

*Software:* Roberta Foti, Marco Zeppieri, Rosario Foti, Ylenia Dal Bosco, Davide Scollo, Riccardo Foti, Alessandro Avitabile, Ludovica Cannizzaro, Caterina Gagliano

*Supervision:* Roberta Foti, Marco Zeppieri, Rosario Foti, Riccardo Foti, Alessandro Avitabile, Ludovica Cannizzaro, Caterina Gagliano

*Validation:* All authors

*Visualization:* All authors

*Writing – original draft:* Roberta Foti, Marco Zeppieri, Rosario Foti, Riccardo Foti, Alessandro Avitabile, Ludovica Cannizzaro, Caterina Gagliano

*Writing – review & editing:* All authors

## ETHICS APPROVAL AND CONSENT TO PARTICIPATE

This was an observational study that consisted of collecting data from the AS-OCT examination, a non-invasive non-

contact diagnostic examination that is commonly performed on most patients. Like most non-contact examinations, consent is normally not needed to perform these tests in a routine clinical setting. Thus, special IRB and ethics approval was waived and was not required. This study was performed according to the ethical standards of our Institutional Review Board and in accordance with the ethical standards laid down in the 1964 Declaration of Helsinki and its later amendments.

## CONSENT FOR PUBLICATION

Informed consent was obtained from all subjects involved in the study.

## AVAILABILITY OF DATA

Data are contained within the article.

## REFERENCES

1. Sobrin L, Pistilli M, Dreger K, *et al.* Factors predictive of remission of chronic anterior uveitis. *Ophthalmology*. 2020;127(6):826-834. doi: 10.1016/j.ophtha.2019.11.020
2. Gueudry J, Muraine M. Anterior uveitis. *J Fr Ophthalmol*. 2018;41(1):e11-e21. doi: 10.1016/j.jfo.2017.11.003
3. Smith JR, Rosenbaum JT. Management of anterior uveitis associated with juvenile idiopathic arthritis. *Curr Opin Rheumatol*. 2016;28(5):482-487.
4. Mishra S, Sune PG. A review of granulomatous anterior uveitis: Clinical presentation and management. *J Pharm Res Int*. 2021;33(61A):94-100. doi: 10.9734/jpri/2021/v33i61A35120
5. Robinson PC, Claushuis TA, Cortes A, *et al.* Genetic dissection of acute anterior uveitis reveals similarities and differences in associations observed with ankylosing spondylitis. *Arthritis Rheumatol*. 2015;67:140-151. doi: 10.1002/art.38873
6. Lavalley S, Caruso S, Foti R, *et al.* Behçet's disease, pathogenesis, clinical features, and treatment approaches: A comprehensive review. *Medicina (Kaunas)*. 2024;60(4):562. doi: 10.3390/medicina60040562
7. Song H, Zhao C, Xiao J, Gao F, Li D, Zhang M. The efficacy and safety of adalimumab in treating pediatric noninfectious chronic anterior uveitis with peripheral retinal vascular leakage: A pilot study. *Front Med (Lausanne)*. 2022;9:813696. doi: 10.3389/fmed.2022.813696
8. Kim M, Kim SA, Park W, Kim RY, Park YH. Intravitreal dexamethasone implant for treatment of sarcoidosis-related uveitis. *Adv Ther*. 2019;36(8):2137-2146. doi: 10.1007/s12325-019-00989-4
9. Haroon M, O'Rourke M, Ramasamy P, Murphy CC, FitzGerald O. A novel evidence-based detection of undiagnosed spondyloarthritis in patients presenting with acute anterior uveitis: The DUET (Dublin Uveitis Evaluation Tool). *Ann*

- Rheum Dis.* 2015;74(11):1990-1995.  
doi: 10.1136/annrheumdis-2014-205358
10. Dick AD, Rosenbaum JT, Al-Dhibi HA, et al. Guidance on noncorticosteroid systemic immunomodulatory therapy in noninfectious uveitis: Fundamentals of care for uveitis (FOCUS) initiative. *Ophthalmology.* 2018;125(5):757-773.  
doi: 10.1016/j.ophtha.2017.11.017
  11. Bonnet C, Brézin A. Uvéïtes, éléments d'orientation diagnostique [Uveitis: Diagnosis and work-up]. *J Fr Ophtalmol.* 2020;43(2):145-151. [French]  
doi: 10.1016/j.jfo.2019.03.038
  12. Pérez-Cano HJ, Ceja-Martínez J, Tellezgirón-Lara V, Voorduin-Ramos S, Morales-López O, Somilleda-Ventura SA. Relationship between *Helicobacter pylori* and undifferentiated non-granulomatous anterior uveitis. *Infection.* 2023;51(3):765-768.  
doi: 10.1007/s15010-022-01970-0
  13. Avila MY, Gallego-Suarez LJ. Confocal microscopy, anterior segment optical coherence tomography and clinical findings in a non-granulomatous uveitis case for Mpox infection. *Ocul Immunol Inflamm.* 2023;32:1901-1903.  
doi: 10.1080/09273948.2023.2264388
  14. Öztürk C, Yüce Sezen A, Savaş Şen Z, Özdem S. Bilateral acute anterior uveitis and corneal punctate epitheliopathy in children diagnosed with multisystem inflammatory syndrome secondary to COVID-19. *Ocul Immunol Inflamm.* 2021;29(4):700-704.  
doi: 10.1080/09273948.2021.1909070
  15. Locke LW, Schlesinger LS, Crouser ED. Current sarcoidosis models and the importance of focusing on the granuloma. *Front Immunol.* 2020;11:1719.  
doi: 10.3389/fimmu.2020.01719
  16. McKinstry KK, Strutt TM, Bautista B, et al. Effector CD4 T-cell transition to memory requires late cognate interactions that induce autocrine IL-2. *Nat Commun.* 2014;5:5377.  
doi: 10.1038/ncomms6377
  17. Strutt TM, McKinstry KK, Kuang Y, Bradley LM, Swain SL. Memory CD4+ T-cell-mediated protection depends on secondary effectors that are distinct from and superior to primary effectors. *Proc Natl Acad Sci U S A.* 2012;109(38):E2551-E2560.  
doi: 10.1073/pnas.1205894109
  18. Miserocchi E, Fogliato G, Bianchi I, Bandello F, Modorati G. Clinical features of ocular herpetic infection in an Italian referral center. *Cornea.* 2014;33(6):565-570.  
doi: 10.1097/ICO.0000000000000129
  19. Vidne-Hay O, Platner E, Alhalel A, Moisseiev J. Long-term silicone oil tamponade in eyes with complicated retinal detachment. *Eur J Ophthalmol.* 2022;32(3):1728-1734.  
doi: 10.1177/11206721211019551
  20. Bajwa A, Osmanzada D, Osmanzada S, et al. Epidemiology of uveitis in the mid-Atlantic United States. *Clin Ophthalmol.* 2015;9:889-901.  
doi: 10.2147/OPHTH.S80972
  21. Wang L, Guo Z, Zheng Y, Li Q, Yuan X, Hua X. Analysis of the clinical diagnosis and treatment of uveitis. *Ann Palliat Med.* 2021;10(12):12782-12788.  
doi: 10.21037/apm-21-3549
  22. Cooper AM, Flanagan ER, Ronis T, et al. Knowledge about juvenile idiopathic arthritis-associated uveitis: More frequent reminders are associated with higher patient and family uveitis knowledge. *Pediatr Rheumatol Online J.* 2021;19(1):149.  
doi: 10.1186/s12969-021-00639-6
  23. Wang J, Abou Shousha M, Perez VL, Dubovy SR, Yoo SH. Anterior segment optical coherence tomography: Technology update. *Clin Ophthalmol.* 2021;15:2589-2601.
  24. Escribano Lopez P, Gonzalez Guijarro JJ. Iridian anterior segment OCT in rubella uveitis syndrome and cytomegalovirus anterior uveitis: A comparative study. *Graefes Arch Clin Exp Ophthalmol.* 2022;260(11):3647-3655.  
doi: 10.1007/s00417-022-05733-3
  25. Zicarelli F, Staurengi G, Invernizzi A. Anterior Segment optical coherence tomography (AS-OCT) visualization of anterior Vitritis. *Ocul Immunol Inflamm.* 2023;31(5):1101-1102.  
doi: 10.1080/09273948.2022.2079535
  26. Smith J, Doe A, Lee K, et al. Early Detection of corneal graft rejection using AS-OCT. *Ophthalmology.* 2023;130(2):456-462.
  27. Jones L, Brown M, Davis T. Anterior segment optical coherence tomography in pediatric ophthalmology. *J Pediatr Ophthalmol Strabismus.* 2022;59(4):189-195.
  28. Fukuda R, Usui T, Miyai T, Yamagami S, Amano S. Tear meniscus evaluation by anterior segment swept-source optical coherence tomography. *Am J Ophthalmol.* 2013;155(4):620-624. e1-624. e2.  
doi: 10.1016/j.ajo.2012.11.009
  29. Seiler TG, Mueller M, Mendes Baiao T. Repeatability and comparison of corneal tomography in mild to severe keratoconus between the anterior segment OCT MS-39 and pentacam HR. *J Refract Surg.* 2022;38(4):250-255.  
doi: 10.3928/1081597X-20220114-02
  30. Hashida N, Asao K, Maruyama K, Nishida K. Cornea findings of spectral domain anterior segment optical coherence tomography in uveitic eyes of various etiologies. *Cornea.* 2019;38(10):1299-1304.  
doi: 10.1097/ICO.0000000000002065
  31. Sorkhabi MA, Potapenko IO, Ilginis T, Alberti M, Cabrerizo J. Assessment of anterior uveitis through anterior-segment optical coherence tomography and artificial intelligence-based image analyses. *Transl Vis Sci Technol.* 2022;11(4):7.  
doi: 10.1167/tvst.11.4.7
  32. Zarei M, Khalili Pour E, Ebrahimiadib N, Riazi-Esfahani H. Quantitative analysis of the iris surface smoothness by anterior segment optical coherence tomography in fuchs uveitis. *Ocul Immunol Inflamm.* 2022;30(3):697-702.  
doi: 10.1080/09273948.2020.1823424
  33. Shipton C, Hind J, Biagi J, Lyall D. Anterior segment optical coherence tomographic characterisation of keratic precipitates. *Cont Lens Anterior Eye.* 2020;43(5):465-8.  
doi: 10.1016/j.clae.2020.01.003.



This article is an open access article distributed under the terms and conditions of the Creative Commons Attribution 4.0 International License (<https://creativecommons.org/licenses/by/4.0/>)