

# End tuberculosis strategy also requires initiation and integration of a national silicosis control program with the ongoing tuberculosis elimination activities: A review of the silicotuberculosis situation in India

Bidisa Sarkar<sup>1</sup>, Kamalesh Sarkar<sup>2\*</sup>

<sup>1</sup>Maldah Unit, National Public Health Support Network, World Health Organization, West Bengal, 732101, India

<sup>2</sup>Indian Council of Medical Research-National Institute of Occupational Health, Ahmedabad, Gujarat, 380016, India

## Abstract

**Background:** Earlier studies conducted by Indian researchers have demonstrated that the elimination of tuberculosis (TB) requires proactive control of silicosis, given India's significant burden of silicosis and its common comorbidity, pulmonary TB, also known as silicotuberculosis. The TB Control Indian Health Authority saw human immunodeficiency virus infection, diabetes, and malnutrition, among others, as important risk factors for case findings, but overlooked the significance of silicosis. Silicotuberculosis control is often confronted with challenges of detecting microorganisms, uncertain treatment outcomes, a higher likelihood of mono-drug and multi-drug resistance, and increased mortality due to treatment failure. In addition, silicosis has a long latent period, typically 15 years or more, from the onset of silica dust exposure to the appearance of opacities on radiological examination, which is the conventional method of diagnosis of the condition.

**Objective:** Facing the aforementioned situation, scientists of the Indian Council of Medical Research-National Institute of Occupational Health have identified a useful biomarker, Club cell secretory protein 16 (CC-16) (a lung protein), that might serve as a surrogate marker for early detection of silicosis among silica dust-exposed workers. An added benefit of CC-16 is its ability to detect sub-radiological silicosis, which is recognized as a risk factor for TB and multi-drug-resistant TB. At present, two researchers have developed point-of-care devices for detecting silica-dust-induced lung damage using serum CC-16, to support its further application. **Conclusion:** The present review highlights possible mechanisms for the early detection of silicosis and silicotuberculosis by assessing several relevant research publications, and the findings suggest that a national silicosis control program, to be integrated with existing TB elimination activities for sustainable and improved outcomes, should be initiated.

**Keywords:** Elimination of tuberculosis, Silicosis, Sub-radiological silicosis, Silicotuberculosis, Club cell secretory protein 16, Surrogate marker, Early detection

## 1. INTRODUCTION

Pulmonary tuberculosis (PTB), an infection of the lungs caused by *Mycobacterium tuberculosis*, is often characterized by chronic cough, gradual weight loss, increasing fatigue, fever, and night sweats. While tuberculosis (TB) commonly affects the pulmonary system, non-PTB is not uncommon. According to the World Health Organization (WHO) Report 2022, there were estimated increases in countries with major shortfalls in TB notifications in 2020 and 2021, including India, Indonesia, Myanmar, and the Philippines [1]. Despite being a preventable and curable disease, TB remains one of the leading infectious killers across the globe, culpable for more than one million deaths annually. India has targeted the elimination of TB by the year 2025. Although significant progress has been made, several challenges need to be addressed before the target can be achieved, such as the

high burden of TB in the country, lack of symptoms in the early stage, poor health-seeking behavior of the infected

\*Corresponding author:  
Kamalesh Sarkar (kamalesh.sarkar@gmail.com)

This is an open-access article under the terms of the Creative Commons Attribution License, which permits use, distribution, and reproduction in any medium, provided the original work is properly cited.

© 2024 Journal of Biological Methods published by POL Scientific

Received: 9 August 2024; Revision received: 4 September 2024;  
Accepted: 23 September 2024; Published: 24 October 2024

**How to cite this article:** Sarkar B, Sarkar K. End tuberculosis strategy also requires initiation and integration of a national silicosis control program with the ongoing tuberculosis elimination activities: A review of the silicotuberculosis situation in India. *J Biol Methods*. 2024;11(4):e99010035. DOI: 10.14440/jbm.2024.0053

population, a substantial gap in case finding, increasing multi-drug-resistant TB (MDR-TB), lack of early detection, poor treatment compliance, high population density, lack of coordination with private physicians and hospital doctors, ineffective outreach to vulnerable groups, and rising treatment costs [2]. In addition, India is under a significant burden of silicosis, which is closely linked to the occurrence of TB, particularly PTB. Notably, silicotuberculosis (TB occurring in the presence of silicosis) is difficult to detect, leading to uncertain treatment outcomes and heightened risk of mono-drug resistance and multi-drug resistance, which can result in treatment failure and higher TB-related mortality.

Globally, MDR-TB poses a significant health threat, challenging efforts to control and eliminate the disease. MDR-TB arises when TB bacteria develop resistance to first-line anti-TB drugs, such as isoniazid and rifampicin. This resistance complicates treatment, often necessitating protracted and more expensive courses of second-line drugs, which may have more severe side effects. Several studies have shed light on the mechanism of bacteria developing drug resistance [3-5]. The compromised respiratory function in individuals with silicosis renders them more susceptible to TB infection, compromising the immune system's ability to fight the disease.

Although the disease burden is high in India, silicosis, as a neglected occupational respiratory condition, has been grossly overlooked in the country. The country's medical curriculum does not effectively cover silicosis and its close connection with TB. As a result, most physicians in the country are not in a position to consider taking an occupational exposure history to arrive at the diagnosis of silicosis. Similarly, they are not trained in radiological identification of silicotic opacities. Furthermore, the long latent period before radiological evidence of silicosis presents another significant challenge. Even before the appearance of radiological opacities, the lungs of affected individuals suffer progressive damage, which increases their vulnerability to PTB and other comorbidities.

## 2. OBJECTIVES

Considering the significant burden of silicosis in India and its correlation to TB, this study aimed to explore approaches that could aid in TB elimination in the country. This article features a strategy to address the issue concerning silicosis and silicotuberculosis with appropriate interventional measures, such as effective management, preventive treatment, and the protection of vulnerable groups.

## 3. LITERATURE RETRIEVAL

An extensive literature review was conducted from May to July 2024, encompassing previous studies and recent

advances in the control of silicosis and silicotuberculosis. Relevant keywords included "Elimination of TB," "Silicosis," "Sub-radiological silicosis," "Silicotuberculosis," "CC-16," "Biomarker," "Surrogate marker," and "Early detection." Search engines such as PubMed/MEDLINE, Google, Scopus, and Science Direct were used to find the most relevant articles. A total of 46 articles were found to be relevant and reviewed. Since early detection followed by effective chemotherapy is the cornerstone of any infectious disease control strategy, it is essential to identify effective early detection markers and locate all vulnerable populations to offer the best possible interventions. Herein, we proposed a mechanism for formulating national and/or sub-national policies and structuring strategies based on the country's needs.

## 4. RESULTS AND DISCUSSION

India is one of the countries with a high TB burden [6]. The End TB Strategy, developed by WHO in 2014, aims to end the global TB epidemic by 2035, targeting a 90% reduction in TB-related morbidities and a 95% reduction in TB-related mortalities, while ensuring that no family faces catastrophic costs for treatment [7].

Despite battling TB for over half a century, it remains one of the biggest public health concerns in India. The National Strategy Plan (NSP) 2017–2025 for TB elimination aims to reduce the incidence, prevalence, and deaths due to TB. The NSP encompasses state and central governments, development partners, the private sector, and civil society. The vision of a TB-free India with zero TB-related deaths, disease, and poverty by 2025 stands on the four pillars of the Detect-Treat-Prevent-Build program [8].

People living with human immunodeficiency virus (HIV), diabetes, and malnutrition are identified as special "at-risk" groups more prone to TB, as emphasized by WHO and the Indian government. Similarly, antibiotic resistance, multidrug resistance, and tobacco use have also been highlighted in the discussions [6,8]. Hence, the NSP 2017–2025 addresses and serves underserved populations, including tribal communities [8].

Despite considering the aforementioned risk groups and special circumstances, one overlooked yet important circumstance is the significant burden of silicosis in India. Silicosis is an often neglected and under-diagnosed occupational respiratory disease that poses a serious public health concern. It is commonly found in under-privileged workers who are exposed to respirable crystalline silica (RCS) dust for a considerable duration. Silicosis is preventable but not curable; once it starts to develop, it progressively worsens, debilitating the person's ability to breathe due to progressive fibrosis of lung tissues and reducing both quality of life and

lifespan [9,10]. Notably, PTB is the common comorbidity in individuals with silicosis due to the progressive destruction of lung macrophages (lung immunity), which remains lifelong even after silica-dust exposure ceases, such as post-retirement.

The burden of silicosis and sub-radiological silicosis is significantly high in India. Silicosis (conventionally diagnosed radiologically) is characterized by bilateral nodular opacities, usually found in the upper part of the lungs, developing over a long time (i.e., 15 years or more from the onset of exposure to radiological appearance) in cases of chronic silicosis. Sub-radiological silicosis may be defined as the early stage of silica dust exposure when a chest X-ray appears normal, but the lungs are damaged due to silica-induced inflammation, which can be confirmed through lung biopsy. Many PTB cases may be associated with sub-radiological silicosis, as inflammation of the lungs impairs their immunity, thereby increasing the risk of TB infection. Studies have also reported an increased lifelong risk for TB even after silica dust exposure ceases [11,12].

Another study investigated the emergence of MDR-TB in silicotuberculosis cases among glass industry workers in the Firozabad District of Uttar Pradesh, India. This study observed that both PTB and MDR-TB were directly proportional to the dose and/or duration of silica dust exposure; the greater the silica dust-induced lung damage, the higher was their risk of infection by both PTB and MDR-TB [13].

The estimated number of silica dust-exposed workers would be 52 million in India by the end of 2025 [14], as a large fraction of Indian society is occupationally exposed to silica dust either continuously or intermittently for long durations due to rapid urbanization, industrialization, and increased population migration. This makes them vulnerable to both silicosis and silicotuberculosis, necessitating periodic screening for the early detection of silica-induced lung damage and silicotuberculosis by using a suitable diagnostic/screening marker.

Club cell secretory protein 16 (CC16) is secreted by the non-ciliated epithelium of terminal bronchioles and functions to maintain lung immunity and epithelial tissue integrity. Serum CC16 level is inversely proportional to damaged lung epithelium and may be used as a surrogate marker to monitor the extent of lung damage in occupationally silica dust-exposed workers [15,16]. Serum CC16 drops due to lung damage, and silicosis aggravates the damage. Consequently, a chest X-ray-based method was developed to assess silicotic lung damage and its relationship with serum CC-16 [17]. Chest X-rays of workers, who were diagnosed with silicosis, were examined in a study conducted by the Indian Council of Medical Research-National Institute of Occupational Health (ICMR-NIOH). International Labor Organization radiography guidelines were used to assess parameters visible on the chest

X-rays: The sizes of the small opacities and large opacities, the profusion of opacities, and the zones of the affected lungs. Each parameter was given a logical value/score for assessing lung damage, and the cumulative scores determined the total silica dust-induced lung damage scoring (LDS) value. The total LDS value was graded as either mild (LDS: 1–6), moderate (LDS: 7–15), or severe (LDS: >15). The study conclusively evidenced that serum CC16 is inversely proportional to the severity of silicotic lung damage among occupational silica dust-exposed workers (compared to the healthy population). This established the hypothesis that serum CC16 levels can be effectively used as a screening measure for assessing silicotic lung damage even before radiological appearance. The study concluded that serum CC16 may be employed as a surrogate or proxy marker for early detection of silicosis among silica dust-exposed workers [17]. In addition, the marker can also detect sub-radiological silicosis [18]. Table 1 indicates various categories of silicotic lung damage and their corresponding serum CC-16 levels that may be used for screening industrial workers for the early detection of silicosis and silicotuberculosis.

As aforementioned, serum CC16 may be considered a surrogate marker for early detection of silicosis by periodic screening of workers with a history of silica dust exposure for a considerable period. Individuals working in a silica-dust environment with reduced serum CC16 levels (<12 ng/mL) usually have silicotic lung damage, in the absence of other lung-damaging conditions. Once silicotic lung damage is detected, it needs to be screened further with a cartridge-based nucleic acid amplification test (CB-NAAT) or similar methods for early detection of silicotuberculosis.

An Australia-based study established that individuals working with artificial stones are also prone to developing

**Table 1. Various serum CC-16 levels and the corresponding silicotic lung damage**

S. No.	Category of silicotic lung damage	Approximate serum CC-16 value
1	Healthy lung	12–20 ng/mL or higher (with an average of 16 ng/mL)
2	Sub-radiological silicosis (not detectable by chest X-ray but by lung biopsy)	9–<12 ng/mL
3	Silicosis with early lung damage which is also evidenced radiologically	6–<9 ng/mL
4	Silicosis with moderate lung damage (evidenced radiologically)	3–<6 ng/mL
5	Silicosis with advanced lung damage (evidenced radiologically)	<3 ng/mL

Notes: (i) Considering biological events variables, the above values apply to the majority with few exceptions, which may overlap with the adjacent categories. (ii) Smoking reduces serum CC-value temporarily to some extent (1–2 ng/mL), which needs to be adjusted by adding 2 ng/mL with heavy smokers (>10 cigarettes or bidi/day) and 1 ng/mL with moderate smokers (5–10 cigarettes or bidi/day). CC-16: Club cell secretory protein 16.

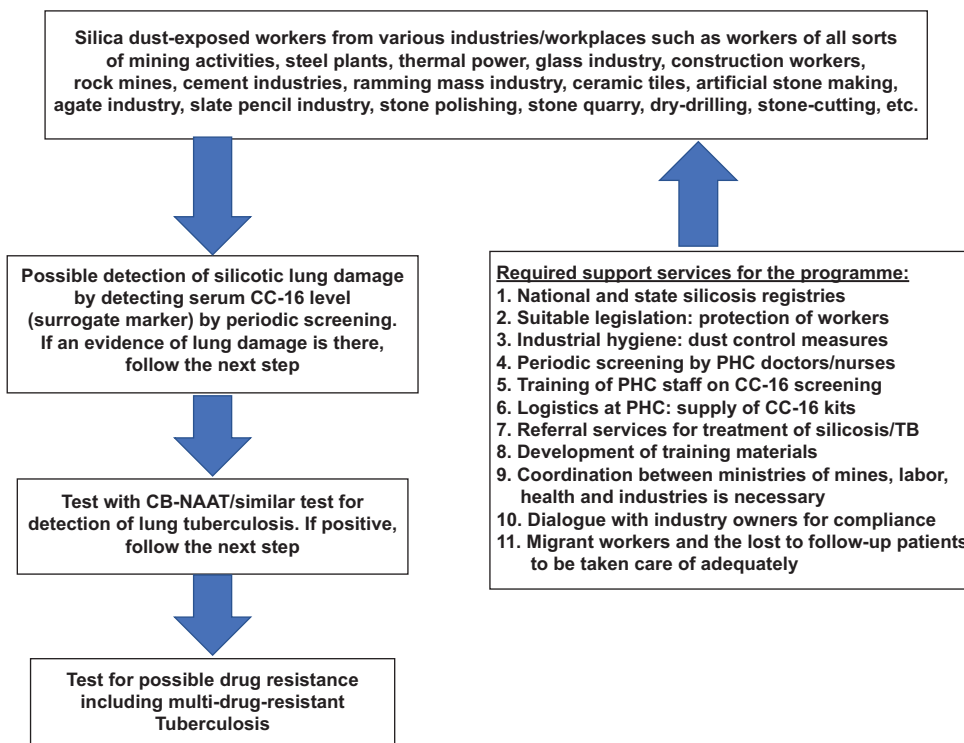
silicosis; this risk is higher for those working in silica dust-heavy environments for prolonged periods, older/malnourished individuals, and habitual smokers [19]. Hence, it is crucial to identify all vulnerable populations to enhance case detection and minimize the gap between estimated and detected cases.

In this regard, silicotic lung damage should be considered a major risk factor for TB as well, alongside HIV, malnutrition, and diabetes. Accordingly, detection, management, and prevention of silicosis and silicotuberculosis are essential. A recent sub-national survey on TB by the ICMR-National Institute of Research in TB reported that 39% of detected TB patients were asymptomatic [20], highlighting the importance of early detection. Early detection and treatment in the pre-symptomatic phase of TB can effectively cure TB patients and prevent its further spread in the community. In view of this, there is an urgent need for the early detection of silicotuberculosis as well. A national silicosis control program should be initiated promptly, integrating existing TB elimination activities in a programmatic manner (Figure 1).

Silica dust-exposed workers from various workplaces (Figure 1) should be periodically screened (at least once a year) to identify possible silicotic lung damage. A study among workers of the Ramming Mass Industry displayed a cluster of acute and accelerated silicosis among the tribal population in the East Singhbhum district of Jharkhand. Of note, the silica content of the dust generated from the

Ramming Mass was high (i.e., >99%), leading to high incidences of acute and accelerated silicosis and PTB among the workers. This occurs when the average dust concentration in the workplace is very high and exposure is considerable. It may be noted that the silica content of the inhaled dust is the most dominant driving force for silica-induced lung damage apart from dust concentration in the workplace and duration of exposure. Another study conducted among sandstone mine workers in Rajasthan also reported a high prevalence of silicosis and PTB [21]. Once silicotic lung damage is identified, further testing with CB-NAAT is recommended for TB detection. If TB is confirmed, the sample should also be tested for potential drug resistance.

Thus, silicosis should be recognized as a major public health concern. Emphasis should be placed on the early detection of silicosis and silicotuberculosis using suitable markers such as serum CC-16. In this regard, two researchers have developed point-of-care devices for detecting serum CC-16 as a marker for silicosis in silica dust-exposed workers, supporting the view that serum CC-16 can serve as a reliable indicator of silicosis [22,23]. Industrial hygienic measures must be adopted accordingly in the workplace. A suitable legislation needs to be made to protect vulnerable silica dust-exposed workers. The country-wide network of Primary Health Center (PHC) staff may be used for the periodic (annual) screening of nearby silica-dust-exposed workers working in informal economy sectors. Suitable



**Figure 1.** Potential pathways for the early detection of silicotuberculosis.

CB-NAAT: Cartridge-based nucleic acid amplification test; PHC: Primary health center; TB: Tuberculosis.

legislation is required to protect vulnerable workers through periodic screening and compliance by the concerned industry owners/employers. The ministries of labor, mines, health, and industry need to collaboratively support this nationwide initiative. PHC staff need to be trained on screening with a point-of-care CC-16 detection kit. ICMR-NIOH and other relevant institutes may supervise the program to address any potential challenges.

## 5. LIMITATIONS

Silicosis is a neglected occupational disease in India, with very few researchers focusing on it. Nonetheless, its close connection with PTB necessitates immediate attention. Although studies indicated that serum CC-16 is a useful predictor of lung damage, it is not specific to silicosis. To overcome this limitation, careful selection of the vulnerable population/workers is essential, specifically those with a history of considerable exposure to RCS dust. Other limitations include the history of current smokers (which requires adjustments) and the absence of any reliable and operational method of detecting sub-radiological silicosis, which is also an important risk factor for PTB and MDR-TB as already evidenced. Hence, assessment using serum CC-16 may be considered to be a feasible alternative for the early detection of silicosis, sub-radiological silicosis, and silicotuberculosis in a programmatic manner.

## 6. CONCLUSION

The early detection of silicosis, sub-radiological silicosis, and silicotuberculosis, as well as the necessary intervention activities, are essential to achieve the targeted elimination/control of both TB and silicosis more rapidly and cost-effectively. Therefore, initiating and integrating the National Silicosis Control Program with the National TB Elimination Program may result in a sustained and improved outcome. Intervention activities include short course TB preventive treatment for high-risk populations and effective management/treatment of TB depending on the situation and as per the guidelines of the country. Screening, diagnosis, and care for associated co-morbidities or other health-related risk factors must be adequately addressed. Similarly, contact investigation, outbreak management, and TB infection prevention and control should not be ignored.

## ACKNOWLEDGMENTS

The authors are grateful to all the silicosis subjects, paramedical personnel, and NGO workers who contributed in various ways to understanding the problems and possible solutions.

## FUNDING

None.

## CONFLICT OF INTEREST

The authors declare no conflicts of interest in any part of this work.

## AUTHOR CONTRIBUTIONS

Both authors have equal contributions.

*Conceptualization:* Kamalesh Sarkar

*Writing – original draft:* Bidisa Sarkar

*Writing – review & editing:* All authors

## ETHICS APPROVAL AND CONSENT TO PARTICIPATE

Not applicable.

## CONSENT FOR PUBLICATION

Not applicable.

## AVAILABILITY OF DATA

Not applicable.

## REFERENCES

1. *Global Tuberculosis Report 2022*. Available from: <https://www.who.int/teams/global-tuberculosis-programme/tb-reports/global-tuberculosis-report-2022> [Last accessed on 2024 Sep 04].
2. Rupani MP, Vyas S, Shah IA. Cohort study on association between catastrophic costs and unfavorable tuberculosis treatment outcomes among TB-HIV and TB-diabetes comorbid patients in India. *BMC Public Health*. 2024;24:2028. doi: 10.1186/s12889-024-19609-0
3. Palomino JC, Martin A. Drug resistance mechanisms in *Mycobacterium tuberculosis*. *Antibiotics (Basel)*. 2014;3: 317-340. doi: 10.3390/antibiotics3030317
4. Almeida Da Silva PE, Palomino JC. Molecular basis and mechanisms of drug resistance in *Mycobacterium tuberculosis*: Classical and new drugs. *J Antimicrob Chemother*. 2011;66:1417-1430. doi: 10.1093/jac/dkr173
5. *WHO Treatment Guidelines for Drug-Resistant Tuberculosis, 2016 Update*. Geneva; 2016. Available from: <https://apps.who.int/iris/bitstream/10665/250125/1/9789241549639-eng.pdf>
6. World Health Organization. *Tuberculosis*. Available from: [https://www.who.int/health-topics/tuberculosis#tab=tab\\_1v](https://www.who.int/health-topics/tuberculosis#tab=tab_1v) [Last accessed on 2024 Jul 07].
7. World Health Organization. *Implementing the End TB Strategy*. Available from: <https://www.who.int/westernpacific/>

- activities/implementing-the-end-tb-strategy#:~:text=who%20developed%20the%20end%20tb,global%20tb%20epidemic%e2%80%9d%20by%202035 [Last accessed on 2024 Jul 07].
8. *National Strategic Plan for Tuberculosis Elimination 2017-2025*. New Delhi: Central TB Division, Directorate General of Health Services, Ministry of Health with Family Welfare, Nirman Bhavan; 2017. Available from: <https://tbcindia.gov.in/writereaddata/nsp%20draft%2020.02.2017%201.pdf> [Last Accessed on 2024 Jun 30].
  9. Lemen RA, Hammond TP. *Silicosis Kills*. Geneva: World Health Organization; 1992.
  10. American Lung Association. *Silicosis*. Available from: <https://www.lung.org/lung-health-diseases/lung-disease-lookup/silicosis> [Last accessed on 2024 Jul 07].
  11. Skowroński M, Halicka A, Barinow-Wojewódzki A. Pulmonary tuberculosis in a male with silicosis. *Adv Respir Med*. 2018;86(3):121-125. doi: 10.5603/ARM.2018.0019
  12. Rees D, Murray J. Silica, silicosis and tuberculosis. *Int J Tuberc Lung Dis*. 2007;11(5):474-484.
  13. Singh D, Sarkar B, Yadav S, Sarkar K. Silent epidemic of silicotuberculosis in India and emergence of multidrug-resistant tuberculosis? *J Glob Antimicrob Resist*. 2024;38:163-166. doi: 10.1016/j.jgar.2024.05.012
  14. Rupani MP. Challenges and opportunities for silicosis prevention and control: Need for a national health program on silicosis in India. *J Occup Med Toxicol*. 2023;18:11. doi: 10.1186/s12995-023-00379-1
  15. Gribben KC, Poole JA, Nelson AJ, et al. Relationships of serum CC16 levels with smoking status and lung function in COPD. *Respir Res*. 2022;23(1):247. doi: 10.1186/s12931-022-02158-8
  16. Biaoxue R, Tian F, Wenlong G, et al. Reduced serum concentration of CC16 is associated with severity of chronic obstructive pulmonary disease and contributes to the diagnosis and assessment of the disease. *Int J Chron Obstruct Pulmon Dis*. 2020;15:461-470. doi: 10.2147/copd.s230323
  17. Sarkar K, Dhatriak S, Sarkar B, Ojha UC, Raghav P, Pagdhune A. Secondary prevention of silicosis and silico-tuberculosis by periodic screening of silica dust exposed workers using serum club cell protein 16 as a proxy marker. *Health Sci Rep*. 2021;4(3):e373. doi: 10.1002/hsr2.373
  18. Sarkar B, Sarkar K, Sarkar R. Potential consequences of screening of occupational silica dust exposed workers for early detection of silicosis/silico-tuberculosis using a novel biomarker, club cell protein-16, with possible intervention by repurposing metformin. *Adv Biomark Sci Technol*. 2023;5:33-37. doi: 10.1016/j.abst.2023.04.001
  19. Hoy RF, Dimitriadis C, Abramson M, et al. Prevalence and risk factors for silicosis among a large cohort of stone benchtop industry workers. *Occup Environ Med*. 2023;80(8):439-446. doi: 10.1136/oemed-2023-108892
  20. Prathiksha G, Selvaraju S, Thiruvengadam K, et al. Programmatic implications of a sub-national TB prevalence survey in India. *Int J Tuberc Lung Dis*. 2024;28:348-353. doi: 10.5588/ijtld.23.0456
  21. Rajavel S, Raghav P, Gupta MK, Muralidhar V. Silico-tuberculosis, silicosis and other respiratory morbidities among sandstone mine workers in Rajasthan- a cross-sectional study. *PLoS One*. 2020;15(4):e0230574. doi: 10.1371/journal.pone.0230574
  22. Ahn C, Lee T, Shin JH, et al. Lab on a chip for detecting Clara cell protein 16 (CC16) for potential screening of the workers exposed to respirable silica aerosol. *Microfluid Nanofluidics*. 2023;27:72. doi: 10.1007/s10404-023-02683-y
  23. Duan K, Xiang Y, Deng Y, Chen J, Liu P. Detection of serum CC16 by a rapid and ultrasensitive magnetic chemiluminescence immunoassay for lung disease diagnosis. *Clin Chem Lab Med*. 2024. doi: 10.1515/cclm-2024-0724



This article is an open access article distributed under the terms and conditions of the Creative Commons Attribution 4.0 International License (<https://creativecommons.org/licenses/by/4.0/>)