

A standardized methodology for longitudinal assessment of corneal endothelial morphometry in eye banked corneas

Zala Lužnik¹, Zhongmou Sun¹, Jia Yin¹, Beth Ann Benetz², Jonathan H. Lass², Reza Dana^{1*}

¹Schepens Eye Research Institute of Massachusetts Eye and Ear, Department of Ophthalmology, Harvard Medical School, Boston, MA 02114, USA

²Cornea Image Analysis Reading Center, Department of Ophthalmology and Visual Sciences, Case Western Reserve University and University Hospitals Eye Institute, Cleveland, OH 44106, USA

*Corresponding author: Reza Dana, E-mail: reza_dana@meei.harvard.edu

Competing interests: Dana R is a consultant for Dompe, Kala, Aldeyra, Novaliq, and Santen.

Abbreviations used: CV, coefficient of variation; ECD, endothelial cell density; ECL, endothelial cell loss; FS, frame score; %Hex, Percentage of hexagonal cells; IQD, image quality grade

Received May 10, 2019; Revision received September 1, 2019; Accepted September 4, 2019; Published November 20, 2019

ABSTRACT

Eye banked research-grade human donor corneas serve as principal *ex vivo* source for studying the mechanisms that underlie corneal endothelial cell damage/death and survival. Wide-field specular microscopy can be used for corneal endothelial visualization and allows for indirect assessment of endothelial cell function by analyzing endothelial cell density (ECD) and morphometric parameters. However, a standardized approach is needed to observe corneal endothelial changes over time. This protocol describes reliable *ex vivo* methods for consecutive analyses of human donor corneal ECD and morphometric parameters change using a wide-field dual imaging specular microscope. This protocol involves tissue warming, acquisition and analysis of specular endothelial images, assessment of corneal layers with the new Enhance mode, optical pachymetry measurement, and qualitative image quality grading scales. This quantitative and qualitative evaluation of donor corneas allows for a systematic analysis of endothelial dynamic responses to *ex vivo* induced stress and can be used as a valuable tool to better elucidate specular findings and mechanisms mediating corneal endothelial cell loss in corneal disease and after transplantation.

Keywords: human donor cornea, corneal endothelium, wide-field dual imaging specular microscopy, eye banking

INTRODUCTION

During the past decade, eye banks have distributed over 166000 cadaveric human donor ocular tissues to researchers in the US [1]. Research-grade human donor corneas have thus become invaluable for developments in eye banking and corneal transplantation. They have served as an excellent *ex vivo* model for studying corneal diseases and new treatment options. In particular, studying donor corneal endothelial cell survival and function after procurement can provide a new platform to better understand the mechanisms that underlie corneal endothelial cell loss (ECL), the leading cause of corneal graft failures, in storage and after transplantation [2].

Standard eye bank specular microscopy enables magnified visualization of central donor corneal endothelial cells and allows for qualitative (e.g., endothelial disease, trauma) as well as quantitative assessment of corneal endothelial cell density (ECD) and morphology features

such as endothelial polymegathism (coefficient of variation (CV)) and pleomorphism (percentage of hexagonal cells (%Hex)) based on an integrated analysis tool [3-5]. The recent introduction of the wide-field *ex vivo* dual imaging specular microscope (CellChek® D+®, Konan Medical, Irvine, CA) has enabled analysis of an even larger viewing area (750000 mm²) [6] with an additional cross-sectional (confocal like) viewing mode (so called Enhance mode) over different corneal layers [7,8]. This new technology thus not only enables more precise donor tissue evaluation in eye banking, it also brings new powerful imaging opportunities into basic research.

However, as is the case in clinical and eye banking settings, the quantitative analysis of ECD and morphometric parameters depends on the reader's ability to correctly understand the specular analysis tools and significant inter- and intra-observer variability may limit data validity [9-11]. Herein, we summarize the recent advances in commonly used eye banking techniques and describe a new standardized protocol for

How to cite this article: Lužnik Z, Sun Z, Yin J, Benetz BA, Lass JH, Dana R. *A standardized methodology for longitudinal assessment of corneal endothelial morphometry in eye banked corneas.* *J Biol Methods* 2019;6(4):e120. DOI: 10.14440/jbm.2019.304

quantitative and qualitative longitudinal evaluation of human donor corneas using a wide-field *ex vivo* dual imaging specular microscope. The protocol was developed to take into consideration the major confounding factors that could skew a proper image evaluation in a research setting.

Our model allows a straightforward reproducible way to observe ECD and morphometric parameters change over time with and without additional pharmacological manipulation in a controlled research environment. Furthermore, the obtained specular endothelial images can be complimented with other commonly used research techniques (such as immunohistochemistry) to further explain the observed morphological findings in a more mechanistic way. This in particular enables high translational use.

MATERIALS

Depending on the protocol tested, paired or non-paired research-grade human donor corneoscleral rims stored in FDA-approved hypothermic storage solution *e.g.*, Optisol-GS (Bausch and Lomb, Rochester NY) or Life4°C (Numedis, Isanti, MN) with their specific storage chambers can be used and issued through eye banks. However, as storage solution composition, chamber design, and viewing platforms vary significantly between different suppliers [12], we recommend using the same storage solution and viewing chamber throughout the study to have less variable outcomes. In addition, to lower the biological variability between donor corneas, we recommend usage of donor corneas with ECD greater than 2000 cells/mm².

Equipment

A calibrated wide-field specular microscope (*e.g.*, the Konan CD-15 specular microscope and CellChekD+ software package; referred to as CellChekD+);

NOTES: Instrument calibration is crucial for accurate morphometry analysis and is required on an annual basis by the FDA [5]. The specular microscope should be calibrated in accordance with the instructions provided by the primary manufacturer. For example, CellChekD+ specular microscope is provided with a 20 µm grid calibration disk set and clear step by step calibration instructions [6]. In brief, 100 µm length is drawn using the calibration disk. The computer software will then indicate a known magnification for 100 µm length (for further instructions see [6] or contact support@konanmedical.com).

- ✓ Hypothermic storage solution (*e.g.*, Optisol-GS; Bausch & Lomb Incorporated; NY; USA; Cat. #STZ50006OPT);
- ✓ Viewing donor cornea chamber (*e.g.*, Bausch & Lomb Incorporated; NY; USA; Cat. #806788);
- ✓ Balanced salt solution (BSS®) sterile irrigating solution, 15 ml Bottle (Alcon®; Cat. #079515);
- ✓ Trypan blue solution, 0.4% (Gibco™; Cat. #15250061);
- ✓ Corning™ Costar™ flat bottom cell culture plates (Cat. #07-200-83);
- ✓ Sterile jeweler's forceps
- ✓ Dry or CO₂ water-jacked incubator (*e.g.*, NAUIRE IR AUT-OFLOW)

PROCEDURE

All paired research-grade human donor corneas used in this study were a courtesy of Eversight Eye Bank (Ann Arbor, MI). **Figure 1** summarizes the protocol steps.

Baseline corneal assessment

1. Masking: before evaluating the corneal endothelium, randomly assign corneas into study or control groups.
2. Cold cornea evaluation: assess the corneal endothelium surface under Finder and Enhance mode for trauma or debris. If debris is left from corneal procurement (such as erythrocytes or iris remnants) gently rinse the endothelium with 1 ml sterile BSS and replace the storage solution.

CAUTION: Warming: place donor corneas (inside their chambers) into a dry or CO₂ water-jacked incubator set at 35°C–37°C for 90 min (CO₂ at 5.0%). After 90 min, check the temperature. If CellChekD+ is used, the temperature can be assessed and saved using the media temperature sensor [6]. If the temperature is ≥ 25°C (and ± 1°C between paired corneas), proceed with specular image evaluation. Otherwise prolong the incubation time for additional 15 min cycles until the desired temperature is reached [12].

3. Trypan blue staining (optional): If endothelial viability needs to be recorded at baseline, place the corneas endothelial side up into a sterile culture plate. Gently rinse the endothelial surface with 1 ml BSS. Add 100 µl trypan blue into the endothelial cup for 60 s. Rinse 2× with 1 ml BSS and place the corneas back into their chamber. Trypan blue will stain damaged endothelial areas blue, which can be easily visualized under Finder mode or as dark nucleated cells under Enhance mode (**Fig. S1**).

Specular microscopy: Image acquisition and cell measurements

4. Selecting the area of interest: assess images from central cornea and 1 to 2 paracentral areas, if possible.

5. Finder mode (4× magnification) (**Fig. 2C**): select the desired area (start with the central area)—save image and move to the Specular mode.
6. Specular mode (**Fig. 2A**): find a sharp endothelial image—save image and move to Enhance mode.

CAUTION: If a sharp endothelial image cannot be obtained, in a research setting, place the corneas back to the incubator for another 2–2.5 h [12,13] and re-evaluate the image quality. If still no sharp endothelial image can be obtained, grade the corneas as unanalyzable (See Troubleshooting).

7. Enhance mode (**Fig. 2D**): save image of the apical surface of the endothelial layer. Reset pachymetry to 0 and move to the epithelial surface of the cornea to obtain the optically assessed pachymetry. Repeat the step 3 times, save each measurement, and calculate the mean.
8. Repeat the steps from 4 to 8 for the paracentral area or proceed with new cornea.

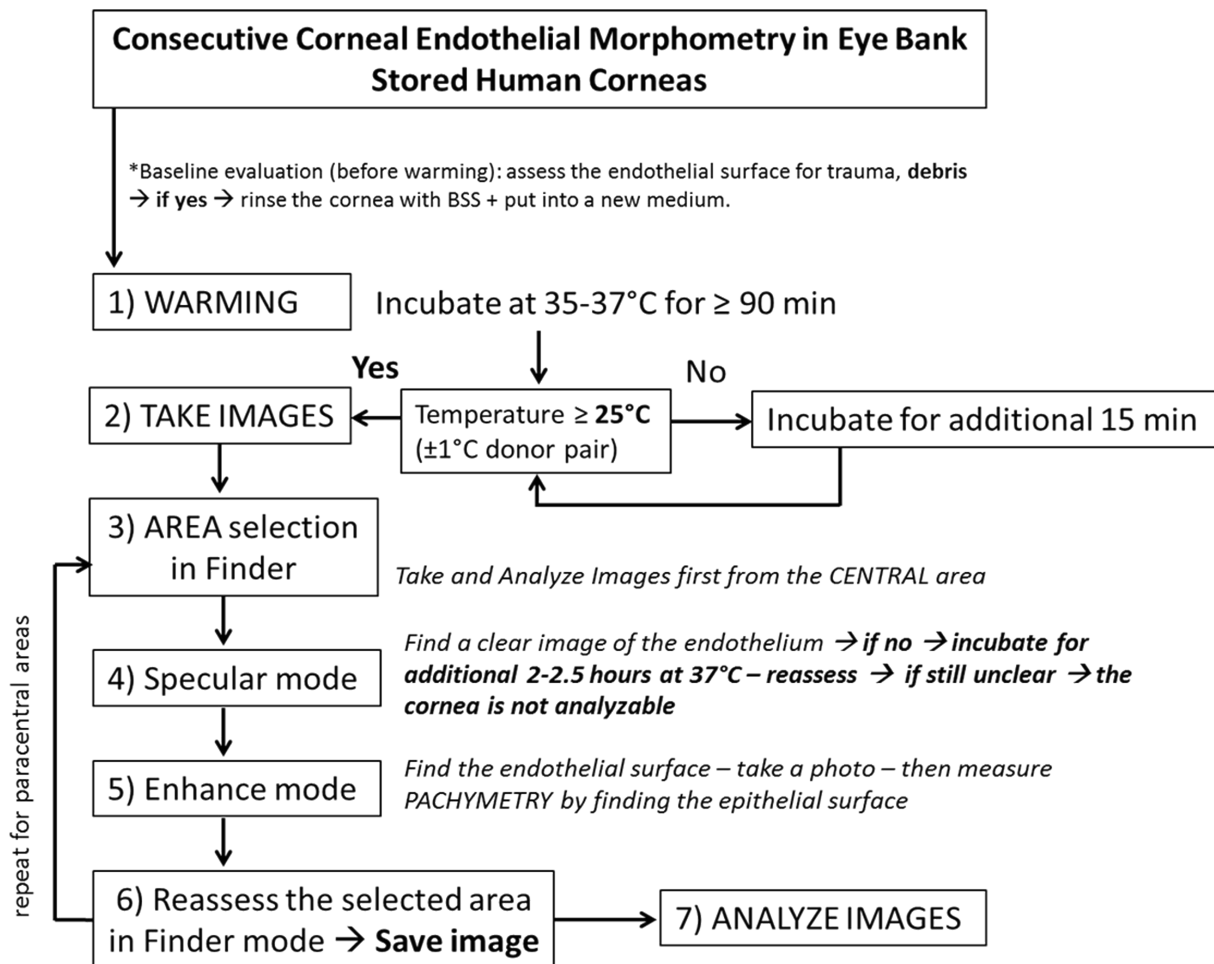


Figure 1. The protocol for longitudinal assessment of corneal endothelial morphometry in eye banked corneas.

Quantitative image analysis: Cell measurements are taken manually using the center method

9. Area selection: select 1–4 areas of clear contiguous cells by placing minimally overlapping rectangular frames.
10. Counting technique: use the FDA-approved Center method [14] for ECD and morphometric analyses.

CRITICAL STEP: Placement of dots will directly influence accuracy of the measurements. Therefore, precisely place dots into the center of each visible cell paying great attention not to count the same cells in different frames. Particular care should be taken to avoid encircling black areas or forming V or U shaped contiguous cell counts (**Fig. 3**). In each frame, count at least 150 contiguous cells. If less than 150 contiguous cell can be identified, count as many as possible. Grade each frame according to the number of analyzable cells (See qualitative image analysis).

NOTES: Morphometry analysis includes (**Fig. 2B**): Endothelial cell density (ECD) (CD = number of cells analyzed/area containing these cells); Cell area analyzed (Ave); Standard deviation of the average cell area (SD); Polymegathism (coefficient of variation, CV = SD/AVE × 100); Pleomorphism (% of 6 sided hexagonal cells); Number of analyzed cells (Num). The incorporated program will calculate these parameters for each frame and report the mean total values for the whole image.

NOTES: After baseline evaluation, proceed with the *ex vivo* experiment (*e.g.*, induction of oxidative stress, adding cytotoxic factors, *etc.*) and store the corneas at 4°C until the next evaluation time point. We recommend evaluating the corneas at least 2 times per week to increase the sensitivity for detecting dynamic morphometric changes. If corneas will be followed for more than 14 d, we recommend a storage solution change at day 10 ± 4 to provide sufficient nutrient supply.

TIPS/HINTS: Qualitative image analysis: Image quality grading scale (**Fig. 4**). To examine the image quality change over time, a semi-quantitative standard approach can be used by grading each frame with a 4-point scoring scale, a modification of previously reported grading scale [5,10,12] to account for the larger viewing area. Each frame is easily gradable based on the maximum number of analyzable (distinct cell borders, contiguous with each other) cells with the Center method and can be graded as score 4 if more than 100 cells were analyzed; as score 3 if 50–99 cells were analyzed; as score 2 if 15–49 cells were analyzed; or score 1 if less than 15 or no cells could be observed. If areas of continues clear cells with unclear cell borders are present in the analyzable frame, subtract 0.5 points from the obtained frame score. The whole wide-field specular image quality is obtained through calculating the algorithmic average of all 4 frames (Image quality = (frame score (FS)1 + FS2 + FS3 + FS4)/4). Excellent and good quality images enable more reliable ECD and morphometric parameter analysis and can be defined as the whole Image Quality Grade (IQG) > 2 (**Fig. 4**).

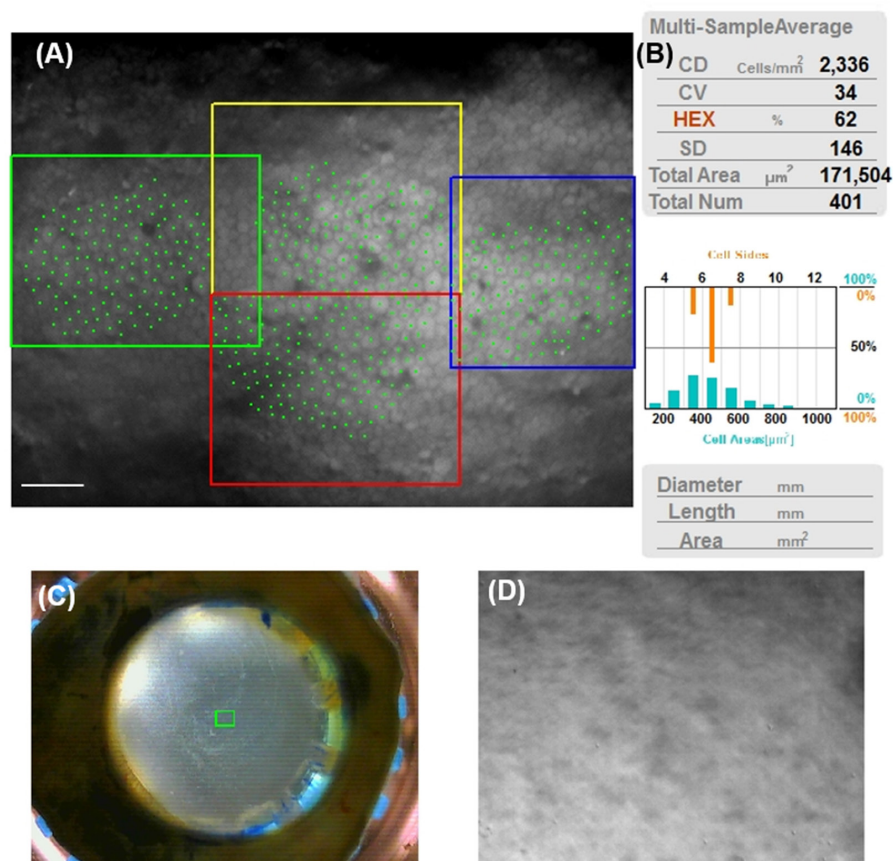


Figure 2. Wide-field *ex vivo* dual imaging specular microscope. **A.** Specular mode with placed 4 rectangular frames for multi-field area analysis. Four discrete areas are selected in the viewing field with a blue, yellow, red and a green rectangular frame. In each frame individual morphometric analytics of marked cells are performed. Scale bar 100 μm. **B.** A consolidated averaged view of the same morphometric parameters calculated individually in the 4 rectangular frames. **C.** Finder mode. **D.** Enhance mode view of the endothelial surface.

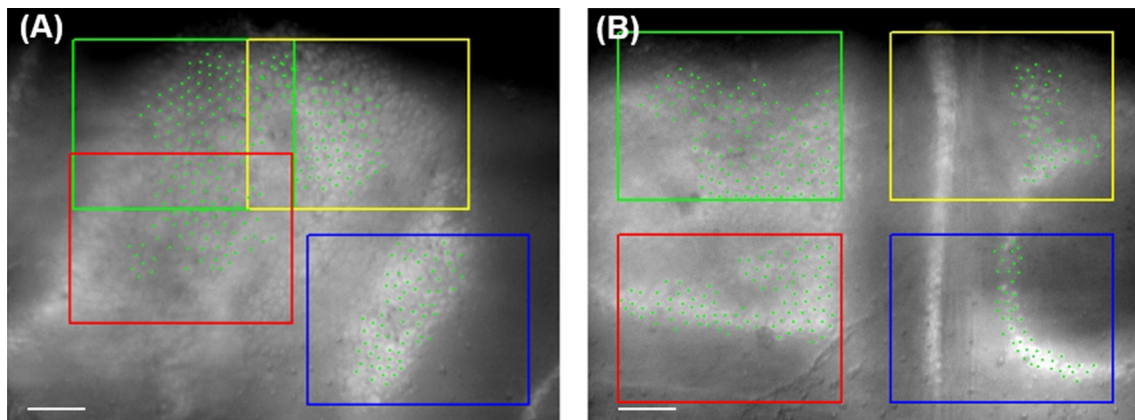


Figure 3. Correct and incorrect image analysis. **A.** Precisely placed dots into the center of each visible cell in a circular fashion in each frame. **B.** Incorrect placement of dots forming L, V or U shapes. Scale bars 100 μm.

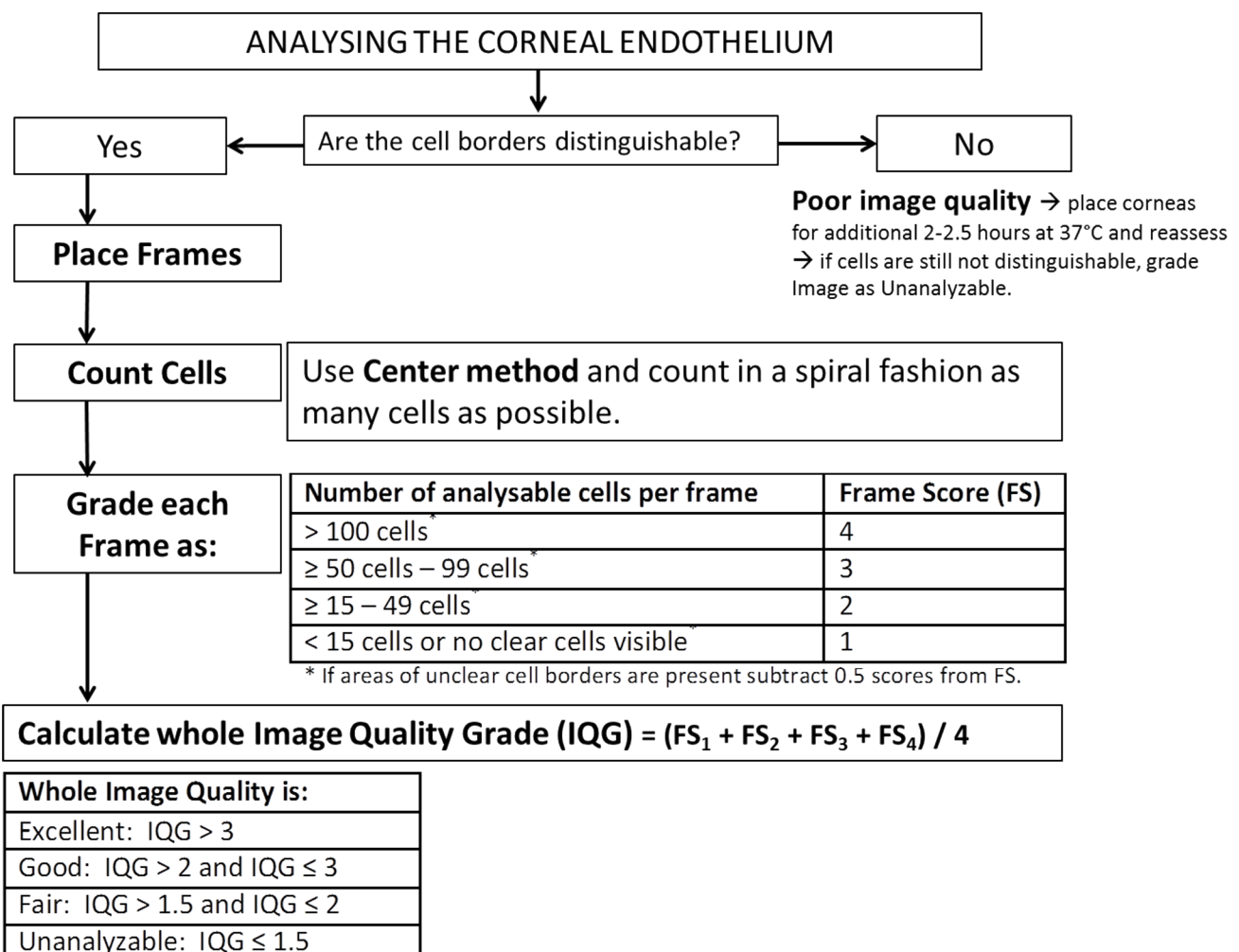


Figure 4. Decision-making flow chart for the image quality grading scale.

ANTICIPATED RESULTS

Specular microscopy can be used in research for visualization of corneal endothelial cell morphology, which enables indirect assessment

of endothelial cell quality over time [15]. Herein, we are introducing a new standardized and reproducible method for precise consecutive *ex vivo* corneal endothelial morphometry using a new wide-field dual imaging specular microscope. This new technology is the first with

an incorporated multi-imaging system (Specular, Enhance and Finder mode) that allows for better donor cornea *ex vivo* evaluation [7].

Figure 5 summarizes the baseline central morphometric changes in corneas that were stored in Optisol-GS for more than 2 weeks without storage solution change or stress induction using our protocol. An expected minimal ECD decline was observed after 7 ($3.5\% \pm 1.6\%$) and 14 ($4.7\% \pm 1.7\%$) d of storage combined with slight fluctuations in CV (day 7: 2.7 ± 1.2 and day 14: 5.3 ± 1.2 increase) and %Hex (day 7: 0.3 ± 1.7 and day 14: 4 ± 0.6 decline). Although not directly comparable,

our results are consistent or even slightly better than observations reported by Means *et al.* [16], where after 9 and 13 d in Optisol-GS cold storage approximately 5% and 7.5% of endothelial cell damage was observed using trypan blue and alizarin red S staining [16]. It is, however, important to note, that after day 14 specular image quality slowly deteriorated due to more pronounced corneal edema and increased light scatter. This was reflected in gradual pachymetry increase (day 7: $9.7\% \pm 1.9\%$; day 14: $13.4\% \pm 2.6\%$; and day 21: $20.2\% \pm 9.0\%$) and visible endothelial folds and cellular debris on Enhance mode.

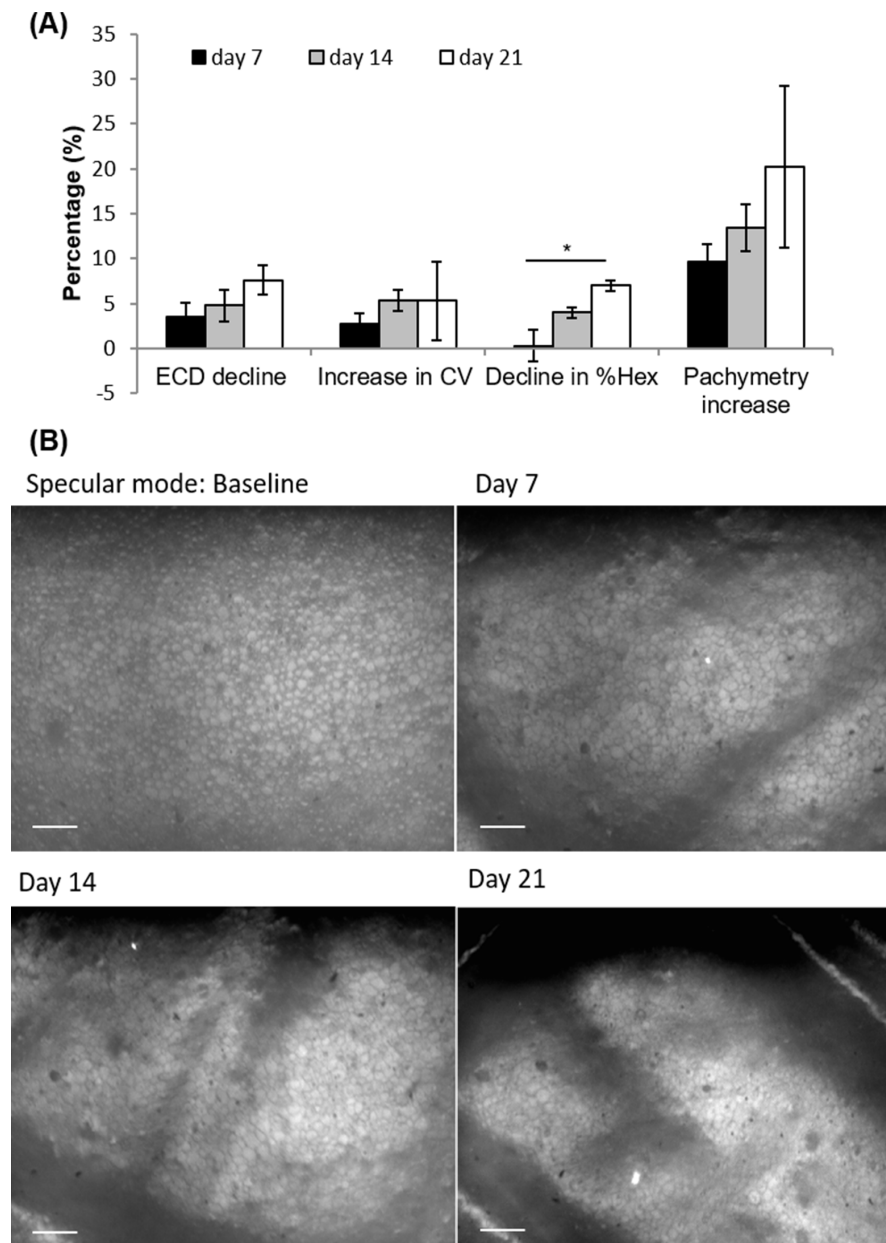


Figure 5. Anticipated donor corneal endothelial morphometry changes over time in hypothermic storage for 3 weeks ($n = 3$). **A.** The mean % of central endothelial cell density (ECD) decline, the increase in coefficient of variation (CV), the decline in % of hexagonal cells (%Hex) ($*P = 0.01$; Repeated Measures ANOVA) and the percentage of pachymetry increase from baseline using this protocol. Data are mean \pm SEM of three samples. For ECD, CV and pachymetry change the difference between each time point is not statistically significant, using paired 2-sided *t*-test ($P > 0.05$). The decline in %Hex is statistically significant between day 7 or 14 and day 21, using a paired 2-sided *t*-test (both $P = 0.02$). **B.** Specular endothelial images from baseline, after 7, 14 and 21 days from the central area. After 2 weeks Descemet's membrane folds with attached endothelium became more pronounced. Scale bars 100 μ m.

As the corneas were stored in a rather small amount of solution (20 ml), storage time and depletion of nutrients may influence those changes in endothelial cell survival and image quality. To date, no good scientific data exist whether storage solution replacement at 4°C–7°C in eye banking is necessary [17]. In clinical practice, if the corneas have been in storage for a maximum of only 7–9 d, no correlation between storage time and the postoperative ECD decline has been observed [18,19]. Results from the Cornea Preservation Time Study also showed that preservation time up to 11 d had little influence on graft success 3 years after lamellar endothelial keratoplasty [17]. Although ECL was significantly greater with longer preservation times, there was little clinical difference in ECL over the 4- to 13-day preservation time range [17]. Therefore, based on our observations, we would suggest a storage solution change at least every 14 d, in order to supply the nutrients for normal metabolic function and survival of cells, if the study will require prolonged dynamic evaluation of hypothermally stored donor corneas.

In addition, low tissue temperature might be an important covariant that can contribute to decreased image quality as well [12]. As previous reports already showed that rapid warming of hypothermally stored donor corneas to near-physiological temperature is superior to room temperature warming [12,13] and allows for more efficient specular imaging without inducing additional ECL or increased pathogen growth [8,13], we incorporated 90 min of rapid (in incubator) tissue warming into our protocol (See also Troubleshooting). Although it is known that donor corneas can be stored in organ culture media between 30°C and 37°C for several weeks with no devastating effect on endothelial cell survival, in the past, the safety of the high molecular weight dextran (a deturgescent agent added to cold storage solutions) was questioned when corneas were preserved at 31°C for several days [20]. Concerns regarding endothelial toxicity might be raised if repeated warm-cold cycles are used. However, after 14 d of repeated warm-cold cycles, we did not observe any diffuse patterns of cell loss suggestive of a global temperature effect, or any evident microbiological contamination. Therefore, we conclude that sequential short time warming (90 min in incubator) of donor corneas has no significant effect on donor endothelial cell loss.

In conclusion, to the best of our knowledge, this is the first report that combines recently published novelties in eye banking to introduce a step by step, standardized methodology for consecutive *ex vivo* donor cornea evaluation using a wide-field dual imaging specular microscope. The overall straightforwardness of this new protocol enables high reproducibility and might not only be used in research, but can also be easily integrated into eye banking for further standardization of protocols used for grading donors corneas for clinical use with the new wide-field dual imaging specular microscopes.

TROUBLESHOOTING

The specular image morphometric measurements and analysis accuracy are highly dependent upon the quality of the specular endothelial image to identify individual cells and how closely the visualized area represents the entire endothelial cell population. Good understanding of the method is necessary to correctly acquire and analyze the data (for a clear overview of the method, see book chapter [14]). Here we discuss some potential issues, particularly problematic in a research setting, and present their solutions.

Insufficient tissue warming

Some corneas require longer warming periods before producing an acceptable specular image [12,13]. Therefore, if after 90 min of dry warming the specular endothelial image is not clear enough (although the chamber temperature is > 25°C) prolong the warming period for another 2–2.5 h. After 4 h the maximal effect of warming on image quality improvement should be reached [13]. If this is not the case, grade the image as unanalyzable. This step is particularly important in research, for being able to successfully differentiate between insufficient warming and image deterioration caused by research manipulation.

Control for intra- and inter-observer variability

To reliably measure morphometric endothelial change over time (especially CV and %Hex) it is extremely important to standardize the reading process. As presented by The Specular Microscopy Ancillary Study (SMAS) each reader should grade 5 good and 10 mixed quality specular images for 3-times and obtain consistent mean measurements (ECD variability in 5% range; CV and %Hex in 15% range) before starting an experiment [10,14]. In addition, a dual-grading procedure with an adjudication process (in case of > 5% ECD variability between readers) should be incorporated to control for inter-observer variability [10,14]. The decision chart is clearly presented in the SMAS [10].

Control for inter-corneal variability

Inter-donor corneal variability can be high and can lead to an increase in the variance of morphometric measurements that can mask the studied effect. Therefore, in addition to the quantitative analysis, we propose to evaluate the image quality change over time with a semi-qualitative image quality grading scale (Fig. 4). To account for the new improvements in specular endothelial technology (*e.g.*, already at baseline evaluation of almost 4-times as many cells as were previously required [7]) we modified the previously reported classification system introduced by The Specular Microscopy Reading Center (SMRC, now the Cornea Image Analysis Reading Center (CIARC)) in 2005 [9,10] to make the grading system more sensitive. We propose to classify the specular endothelial image quality based on the average grade obtained from all four frames' scores. With this method the reader tries to assess the maximal number of countable continues cells per frame, paying great attention to precisely center the dots, as dot placement directly influences the accuracy of the morphometric measurements [14]. This may help to increase the power to correctly observe a change in ECD, CV or %Hex, as more cells are counted and analyzed.

Random versus direct cell comparison

Even in the most ideal imaging conditions with the new wide field specular microscopes, only approximately 0.1% of the whole endothelium can be directly evaluated by specular microscopy [15]. To obtain enough cells for a reliable morphometric analysis in our model, we decided to specify the central area defined by the Finder mode and 1–2 paracentral areas with the highest image quality. However, some research study models might need to focus on visualizing the same cells over a short period of time (*e.g.*, calibration procedures). This can be achieved by different marking techniques such as: using pre-existent 'procurement' asymmetries in the corneoscleral rims as orientation marks; corneoscleral rim incisions (I and II 90 degrees apart) for easier orientation under Finder mode; or as recently reported the placement of an endothelial keratoplasty S-stamp in the center of the donor cornea

[8]. However, apart from the possibility to induce endothelial toxicity, if trypan blue is used, the stamp will fade away in a few days and is less applicable for longer observation.

Acknowledgments

Funding/Support: This work was supported by the NIH R21 EY029387 (Dana R, principal investigator), National Eye Institute (NEI) 5K12EY016335 (Yin J, trainee), Eversight grant (Dana R, principal investigator), Eye Bank Association of America Richard Lindstrom Research Grant (Lužnik Z, principal investigator), Research to Prevent Blindness, Inc. (Lass JH and Benetz BA). The funding source had no direct involvement in study design, in the collection, analysis and interpretation of data, in the writing of the report, or in the decision to submit the article for publication.

References

1. Stamer WD, Williams AM, Pflugfelder S, Coupland SE (2018) Accessibility to and quality of human eye tissue for research: A cross-sectional survey of ARVO members. *Invest Ophthalmol Vis Sci* 59: 4783-4792. doi: [10.1167/iovs.18-25319](https://doi.org/10.1167/iovs.18-25319). PMID: [30304462](https://pubmed.ncbi.nlm.nih.gov/30304462/)
2. Heinzlmann S, Böhringer D, Eberwein P, Reinhard T, Maier P (2016) Outcomes of Descemet membrane endothelial keratoplasty, descemet stripping automated endothelial keratoplasty and penetrating keratoplasty from a single centre study. *Graefes Arch Clin Exp Ophthalmol* 254: 515-522. doi: [10.1007/s00417-015-3248-z](https://doi.org/10.1007/s00417-015-3248-z). PMID: [26743748](https://pubmed.ncbi.nlm.nih.gov/26743748/)
3. Matsuda M, Yee RW, Glasser DB, Geroski DH, Edelhauser HF (1986) Specular microscopic evaluation of donor corneal endothelium. *Arch Ophthalmol* 104: 259-262. doi: [10.1001/archoph.1986.01050140117031](https://doi.org/10.1001/archoph.1986.01050140117031). PMID: [3947301](https://pubmed.ncbi.nlm.nih.gov/3947301/)
4. McCarey BE, McNeill JI (1977) Specular microscopic evaluation of donor corneal endothelium. *Ann Ophthalmol* 9: 1279-1283. PMID: [335947](https://pubmed.ncbi.nlm.nih.gov/335947/)
5. Benetz BA, Lass JH (2018) Specular Microscopy. *Cornea* 37 Suppl 1: doi: [10.1097/ICO.0000000000001642](https://doi.org/10.1097/ICO.0000000000001642). PMID: [29734203](https://pubmed.ncbi.nlm.nih.gov/29734203/)
6. CellChek D donor corneal analysis [Internet]. Konan Medical USA, Inc. Available from: <https://konanmedical.com/cellchek-d/>.
7. Gray KE (2018) Wide-field ex vivo dual imaging microscopy. *Cornea* 37 Suppl 1: doi: [10.1097/ICO.0000000000001644](https://doi.org/10.1097/ICO.0000000000001644). PMID: [29734205](https://pubmed.ncbi.nlm.nih.gov/29734205/)
8. Tran KD, Clover J, Odell K, Chamberlain W, Stoeger CG (2016) Comparison of endothelial cell measurements by two eye bank specular microscopes. *Int J Eye Bank* 4.
9. Lass JH, Gal RL, Ruedy KJ, Benetz BA, Beck RW, et al. (2005) An evaluation of image quality and accuracy of eye bank measurement of donor cornea endothelial cell density in the specular microscopy ancillary study. *Ophthalmology* 112: 431-440. doi: [10.1016/j.ophtha.2004.10.045](https://doi.org/10.1016/j.ophtha.2004.10.045). PMID: [15745770](https://pubmed.ncbi.nlm.nih.gov/15745770/)

10. Benetz BA, Gal RL, Ruedy KJ, Rice C, Beck RW, et al. (2006) Specular microscopy ancillary study methods for donor endothelial cell density determination of cornea donor study images. *Curr Eye Res* 31: 319-327. doi: [10.1080/02713680500536738](https://doi.org/10.1080/02713680500536738). PMID: [16603465](https://pubmed.ncbi.nlm.nih.gov/16603465/)
11. Benetz BA, Stoeger CG, Patel SV, O'Brien RC, Szczotka-Flynn LB, et al. (2019) Comparison of donor cornea endothelial cell density determined by eye banks and by a central reading center in the cornea preservation time study. *Cornea* 38: 426-432. PMID: [16603465](https://pubmed.ncbi.nlm.nih.gov/16603465/)
12. Pham C, Hellier E, Vo M, Szczotka-Flynn L, Benetz BA, et al. JH (2013) Donor endothelial specular image quality in Optisol GS and Life4°C. *Int J Eye Bank* 1. doi: [10.7706/ijeb.v1i2.52](https://doi.org/10.7706/ijeb.v1i2.52).
13. Tran KD, Clover J, Ansini A, Stoeger CG, Terry MA (2017) Rapid warming of donor corneas is safe and improves specular image quality. *Cornea* 36: 581-587. doi: [10.1097/ICO.0000000000001166](https://doi.org/10.1097/ICO.0000000000001166). PMID: [28257386](https://pubmed.ncbi.nlm.nih.gov/28257386/)
14. Sayegh RR, Benetz BA, Lass JH (2016) *Specular Microscopy*. In: Mannis MJ, Holland EJ, editors. *Cornea* (2-Volume Set 4th Edition). Elsevier Inc. pp. 160-179.
15. McCarey BE, Edelhauser HF, Lynn MJ (2008) Review of corneal endothelial specular microscopy for FDA clinical trials of refractive procedures, surgical devices, and new intraocular drugs and solutions. *Cornea* 27: 1-16. doi: [10.1097/ICO.0b013e31815892da](https://doi.org/10.1097/ICO.0b013e31815892da). PMID: [18245960](https://pubmed.ncbi.nlm.nih.gov/18245960/)
16. Means TL, Geroski DH, Hadley A, Lynn MJ, Edelhauser HF (1995) Viability of human corneal endothelium following Optisol-GS storage. *Arch Ophthalmol* 113: 805-809. doi: [10.1001/archoph.1995.01100060131047](https://doi.org/10.1001/archoph.1995.01100060131047). PMID: [7786224](https://pubmed.ncbi.nlm.nih.gov/7786224/)
17. Lass J, Benetz BA, Verdier DD, Szczotka-Flynn LB, Ayala AR, et al. (2017) Corneal endothelial cell loss 3 years after successful descemet stripping automated endothelial keratoplasty in the cornea preservation time study: A randomized clinical trial. *JAMA Ophthalmol* 135: 1394-1400. doi: [10.1001/jamaophthalmol.2017.4970](https://doi.org/10.1001/jamaophthalmol.2017.4970). PMID: [29127432](https://pubmed.ncbi.nlm.nih.gov/29127432/)
18. Terry MA, Shamie N, Straiko MD, Friend DJ, Davis-Boozer D (2010) Endothelial keratoplasty: the relationship between donor tissue storage time and donor endothelial survival. *Ophthalmology* 118: 36-40. doi: [10.1016/j.ophtha.2010.04.029](https://doi.org/10.1016/j.ophtha.2010.04.029). PMID: [20723995](https://pubmed.ncbi.nlm.nih.gov/20723995/)
19. Lass JH, Benetz BA, Gal RL, Kollman C, Raghinaru D, et al. (2013) Donor age and factors related to endothelial cell loss 10 years after penetrating keratoplasty: Specular Microscopy Ancillary Study. *Ophthalmology* 120: 2428-2435. doi: [10.1016/j.ophtha.2013.08.044](https://doi.org/10.1016/j.ophtha.2013.08.044). PMID: [24246826](https://pubmed.ncbi.nlm.nih.gov/24246826/)
20. Pels E, Schuchard Y. The effects of high molecular weight dextran on the preservation of human corneas. *Cornea* 3: 219-227. PMID: [6085762](https://pubmed.ncbi.nlm.nih.gov/6085762/)

Supplementary information

Figure S1. Wide-field specular microscopy images before and after trypan blue staining of the same donor cornea.

Supplementary information of this article can be found online at <http://www.jbmethods.org/jbm/rt/suppFiles/304>.



This work is licensed under a Creative Commons Attribution-Non-Commercial-ShareAlike 4.0 International License: <http://creativecommons.org/licenses/by-nc-sa/4.0>